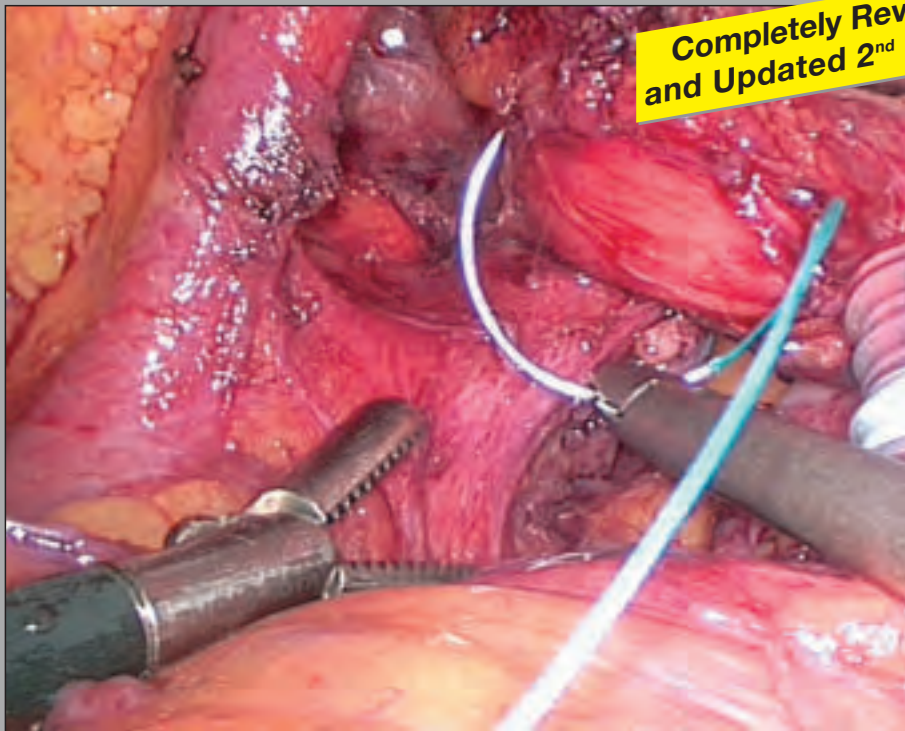


LAPAROSCOPIC FUNDOPLICATION

FOR THE TREATMENT OF
GASTROESOPHAGEAL REFLUX DISEASE



Completely Revised
and Updated 2nd Edition

Prof. Karl-Hermann FUCHS, M.D.

Frankfurter Diakonie-Kliniken
Markus-Krankenhaus, Department of General Surgery,
Visceral, Vascular and Thoracic Surgery
Frankfurt am Main, Germany

**LAPAROSCOPIC FUNDOPLICATION
FOR THE TREATMENT OF
GASTROESOPHAGEAL REFLUX DISEASE**

Prof. Karl-Hermann FUCHS, M.D.

Frankfurter Diakonie-Kliniken
Markus-Krankenhaus, Department of General Surgery,
Visceral, Vascular and Thoracic Surgery
Frankfurt am Main, Germany

Laparoscopic Fundoplication for the Treatment of Gastroesophageal Reflux Disease

Prof. **Karl-Hermann FUCHS**, M.D.

Frankfurter Diakonie-Kliniken

Markus-Krankenhaus, Department of General Surgery,
Visceral, Vascular and Thoracic Surgery
Frankfurt am Main, Germany

Address for correspondence:

Chefarzt Prof. Dr. med. **Karl-Hermann Fuchs**

Frankfurter Diakonie-Kliniken

Markus-Krankenhaus

Klinik für Allgemein Chirurgie, Viszeral-, Gefäß- und
Thorax-Chirurgie

Ginnheimer Landstraße 94

60487 Frankfurt am Main

Phone: +49 69 / 95 33-22 12

Fax: +49 69 / 95 33-26 79

E-mail: karl-hermann.fuchs@fdk.info

© 2014 Endo:Press® Tuttlingen

ISBN 978-3-89756-512-8, Printed in Germany

P.O. Box D-78503 Tuttlingen

Phone: +49 (0) 74 61/1 45 90

Fax: +49 (0) 74 61/7 08-529

E-Mail: Endopress@t-online.de

Editions in languages other than English and German are in preparation. For up-to-date information, please contact Endo:Press® Tuttlingen, Germany, at the address indicated above.

Please note:

Medical knowledge is constantly changing. As new research and clinical experience broaden our knowledge, changes in treatment and therapy may be required. The authors and editors of the material herein have consulted sources believed to be reliable in their efforts to provide information that is complete and in accordance with the standards accepted at the time of publication. However, in view of the possibility of human error by the authors, editors, or publisher of the work herein, or changes in medical knowledge, neither the authors, editors, publisher, nor any other party who has been involved in the preparation of this work, can guarantee that the information contained herein is in every respect accurate or complete, and they cannot be held responsible for any errors or omissions or for the results obtained from use of such information. The information contained within this brochure is intended for use by doctors and other health care professionals. This material is not intended for use as a basis for treatment decisions, and is not a substitute for professional consultation and/or use of peer-reviewed medical literature.

Some of the product names, patents, and registered designs referred to in this booklet are in fact registered trademarks or proprietary names even though specific reference to this fact is not always made in the text. Therefore, the appearance of a name without designation as proprietary is not to be construed as a representation by the publisher that it is in the public domain.

Graphics:

The illustrations were provided by **MED-DESIGN**,
Katja Dalkowski, M.D., Grasweg 42, D-91054 Buckenhof,
E-mail: Kdalkowski@online.de

Typesetting and color reproduction:

Endo:Press® Verlag, D-78532 Tuttlingen, Germany

Printed by:

Straub Druck+Medien AG

D-78713 Schramberg, Germany

05.14-0.2

All rights reserved. No part of this publication may be translated, reprinted or reproduced, transmitted in any form or by any means, electronic or mechanical, now known or hereafter invented, including photocopying and recording, or utilized in any information storage or retrieval system without the prior written permission of the copyright holder.

Contents

1.0	Introduction	6
2.0	Historical Development of Surgical Procedures for the Treatment of Gastroesophageal Reflux Disease	6
3.0	Clinical Aspects of Gastroesophageal Reflux Disease	7–9
4.0	The “Antireflux Barrier” and the Pathophysiology of Reflux	10–11
5.0	Surgical Treatment Concepts	11
6.0	Indications for Antireflux Surgery	12
7.0	Nissen-DeMeester Technique of Laparoscopic Fundoplication	13–20
8.0	Partial Fundoplications	21
9.0	Selecting the Optimum Procedure	22–24
10.0	Discussion	24–25
11.0	References	26–30
	Recommended Instrument Set for Laparoscopic Gastric Surgery (e.g., Fundoplication, Gastric Banding)	
	Telescopes, Trocars, Operating Instruments, and Accessories KARL STORZ IMAGE1 SPIESS™ Camera System, Accessories for Illumination, Video Documentation, and Data Archiving	
	Excerpts from the Following Catalogs: Laparoscopy and Telepresence, Imaging Systems, Documentation, and Illumination	31–61

1.0 Introduction

Gastroesophageal reflux disease has become a major public health problem in our industrialized society. Up to 40% of the U.S. population claim to have at least one episode of heartburn every month⁷⁴. It is reasonable to assume that approximately 10% of the population of industrialized countries seek therapeutic help for reflux-related complaints at some time, and that 10% of this subpopulation suffer from a severe form of reflux disease. This benign functional disorder of the gastrointestinal tract is based on the excessive reflux of gastric juice and gastric contents into the esophagus, causing damage to the esophageal mucosa and/or clinical complaints. Reflux disease can produce a variety of complaints, due in part to its multifactorial etiology, leading to clinical and diagnostic uncertainties that even make it difficult to establish a precise definition for the disease^{16, 33}.

Today, reflux disease has become a focal point of interest owing to three main developments that have taken place during the last 10 years:

- The development of *proton pump inhibitors*, which provide a very efficient medical therapy^{46, 82}.
- The development of *laparoscopic surgery*, which provides an attractive alternative to open surgery^{10, 13, 14, 15, 34}.
- The link between *long-standing reflux disease* and the development of *Barrett esophagus*, which is at increased risk for malignant transformation^{25, 31, 50, 56}.

In this booklet we will explore the various aspects of gastroesophageal reflux disease, review current surgical treatment options, and offer recommendations on techniques and instrumentation.

2.0 Historical Development of Surgical Procedures for the Treatment of Gastroesophageal Reflux Disease

In the past, the frequent link between reflux disease and the presence of a hiatal hernia was considered proof that the anatomical changes associated with hiatal hernia were solely responsible for the reflux disease. Accordingly, surgical efforts in the early decades of the 20th century and even during the 1960s and 1970s were directed mainly toward restoring the anatomy of the gastroesophageal junction^{3, 8, 9, 40, 72}. We do not know who performed the first antireflux operation in the early part of the 20th century.

The first surgical techniques for restoring an anatomically intact gastroesophageal junction were popularized in the early 1950s by *Allison*. His procedure involved a left transthoracic approach, an incision in the hernial sac or phrenoesophageal membrane, and a counterincision in the diaphragm, allowing the herniated part of the stomach to be pulled back into

the abdomen to correct the hernia³. While it was later found that the reconstruction of an anatomically normal gastroesophageal junction did lower the pressure level in the lower esophageal sphincter to some degree, it was also found that 50% of the patients continued to have abnormal gastroesophageal acid reflux¹⁸. *Allison* himself reported this high failure rate in a retrospective survey of his cases published in the early 1970s, at the end of his career³.

Belsey introduced a refined and modified version of the *Allison* operation in which the esophagus was mobilized without incision of the diaphragm, and the distal esophagus (lower esophageal sphincter region) was attached to the gastric fundus and diaphragm to reduce and stabilize the hernia. This operation was successfully performed by the *Belsey* and *Skinner* school in many hundreds of patients^{51, 55, 72}.

Perhaps the most widely practiced antireflux operation is the Nissen fundoplication. *Rudolf Nissen* excised a distal esophageal ulcer in a patient in 1936, then pulled the gastric fundus upward and wrapped it around the oversewn excision site⁵⁴. On seeing this patient again more than 15 years later, he learned that the patient had been completely free of reflux complaints. This led Nissen to perform a fundoplication in two more patients in the mid-1950s, involving the placement of a complete fundic wrap around the region of the lower esophageal sphincter. He published these cases in 1956 and subsequently performed the operation in many hundreds of patients. Later the Nissen fundoplication was modified in many different variants^{17, 19, 20,}

^{34, 39, 62, 68}.

A familiar modification is the Nissen-Rossetti fundoplication, which in its original version did not include mobilization of the greater curvature. Two sutures were used to fix the anterior part of the fundoplication to the anterior gastric wall⁶².

Authors devised and advocated a variety of pexy techniques in the belief that gastroesophageal reflux disease was caused less by an incompetent lower esophageal sphincter than by weakening of the antireflux barrier due

to a lack of longitudinal esophageal tension, leading to deficient spiral fiber closure of the distal esophagus^{49,77}. Unfortunately, the simple anatomic reconstruction of a hiatal hernia and restoration of longitudinal tension to the esophagus by a gastropexy, fundophrenicopexy, or posterior gastropexy as advocated by Hill, as well as ligamentum teres plasty, yielded disappointing results with a relatively high rate of recurrent reflux. As a result, all but a few of these procedures were subsequently abandoned^{36, 40}.

While plastic implants for the repair of diaphragm defects were already being tested in the early 1960s, *Angelchick* was the first to develop a successful antireflux prosthesis that was placed around the gastroesophageal junction^{4, 35, 37}. Material problems led to some unusual complications in the initial phase, which were subsequently corrected. One problem remained, however: an unacceptably high rate of persistent post-operative dysphagia, making it necessary to remove the prosthesis in a reported 10–15% of cases^{47, 48, 70, 76}.

The Angelchick prosthesis has been successfully used in the U.S., but it has not been widely employed in Europe.

3.0 Clinical Aspects of Gastroesophageal Reflux Disease

Although the dominant clinical features of reflux disease are specific symptoms such as heartburn and regurgitation, careful questioning of most patients will elicit a broad spectrum of additional symptoms.

The classic symptom of gastroesophageal reflux disease is heartburn, which is present in 68–85% of reflux patients. Formerly, two types of patients were distinguished based on the circadian timing of their heartburn: “upright refluxers,” who experience post-prandial reflux complaints and belching throughout the day, and “supine refluxers,” who experience reflux complaints mainly after retiring at night. A very characteristic symptom is regurgitation. It differs from vomiting by the absence of associated symptoms

such as nausea, retching, or thoracoabdominal muscle contractions.

Dysphagia is present in up to 30% of patients with reflux disease. By contrast, odynophagia, or painful swallowing, is a relatively rare symptom⁴⁵. Both symptoms frequently result from a peptic stricture in reflux patients. In rare cases they are caused entirely by esophagitis, a Schatzki ring, or an esophageal motility disorder.

Epigastric pain is described as the most common symptom of reflux disease. It is combined with heartburn or regurgitation in most patients, but in 10–20% of cases it is the only presenting symptom of reflux disease.

The most common respiratory symptoms of reflux disease are nocturnal awakening with cough and dyspnea, morning hoarseness, and recurrent bronchospastic episodes⁶³. These symptoms are often predominant, especially in children. Nausea and vomiting are other nonspecific symptoms. Because they also occur in a variety of diseases in the upper gastrointestinal tract, they serve more as suggestive signs than definitive criteria.

The complications of gastroesophageal reflux disease are erosive esophagitis, strictures, ulcers, and the development of a specialized columnar epithelium with intestinal metaplasia (Barrett esophagus)^{5, 21, 31, 65}.

Esophagitis is caused by chronic irritation of the esophageal mucosa by gastric juices, resulting in a loss of superficial epithelial cells. Opinions vary as to whether esophagitis is a symptom or a complication of reflux disease, due largely to an overlap in the definition of the terms "reflux disease" and "reflux esophagitis."

Peptic esophageal stricture results from long-term damage to the esophageal mucosa due to intestinal secretions. It always develops at the junction of squamous epithelium and columnar epithelium.

An esophageal ulcer may develop at the transition zone between columnar and squamous epithelium ("gastroesophageal junction ulcer"), where it usually causes or contributes to stricture formation. Frequently, however, a "Barrett ulcer" will develop in the columnar epithelium of a Barrett esophagus^{31, 56}. To date, the very rare complications of penetration or perforation have been observed only in patients with a Barrett ulcer. The underlying pathophysiologic mechanism is an excessive reflux of gastric juice into the esophagus followed by mucosal damage and/or clinical complaints. The variety of complaints that may arise, the multiple causal factors that contribute to abnormal reflux, and the individual resistance of the esophageal mucosa to refluxed material lead to clinical and diagnostic uncertainties which make it difficult to establish a precise definition for the disease^{16, 33}. In the past, reflux disease was defined radiographically by the presence of a hiatal hernia at the gastroesophageal junction and the ability to provoke the reflux of contrast medium during x-ray examination. The relationship between hiatal hernia and reflux disease continues to be a controversial issue. The incidence of axial hiatal hernia, usually a sliding form, increases with aging. Most persons with a hiatal hernia do not have abnormal reflux, suggesting that an axial hiatal hernia does not necessarily have pathologic significance in reflux disease. Conversely, it is now known that a hiatal hernia can be detected in approximately 80% of patients with reflux disease, and that the morphologic changes associated with an hiatal hernia can promote a pathologic reflux mechanism^{8, 16, 21}.

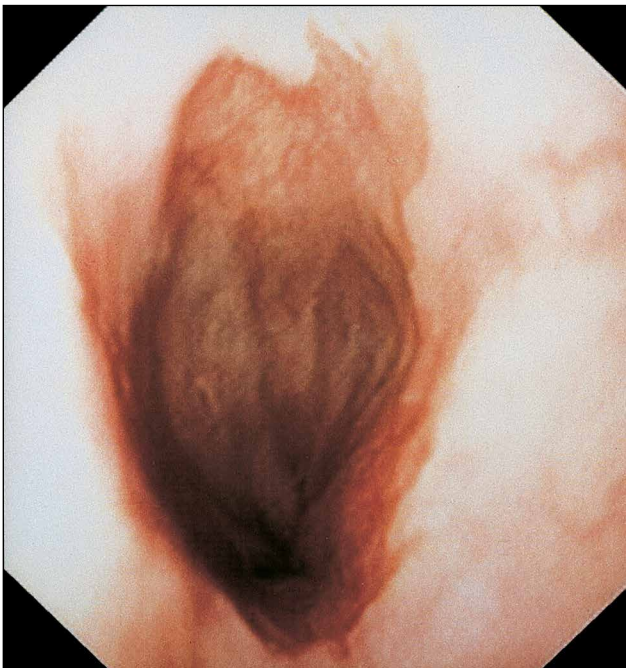


Fig. 3.1
Barrett esophagus.

During the past 20 years, gastroesophageal reflux disease has been defined on the basis of endoscopically detectable reflux esophagitis^{5,65}. But a great many patients suffer from mild or severe reflux complaints in the absence of endoscopically detectable esophagitis, and so we cannot claim that endoscopy provides optimum sensitivity or specificity in defining the disease³³. One way to formulate a precise definition of gastroesophageal reflux disease (GERD) is to base the definition on the pathophysiologic mechanism that underlies the disease process. GERD is present when gastric contents enter the esophagus in an abnormal quantity or abnormal composition, leading to specific and nonspecific symptoms and/or damage to the esophageal mucosa. The following definition is in common use: GERD is present when there is risk of organic complications due to increased gastroesophageal reflux and/or quality of life is adversely affected due to reflux-related complaints.

Thus, the diagnosis of GERD relies critically on the precise detection of gastric contents in the esophagus, whether in the form of acidic gastric juice or mixed gastric contents that have refluxed from the duodenum. Owing to diagnostic advances, particularly computer-assisted methods such as 24-hour pH monitoring of the esophagus and stomach, long-term aspiration tests, and fiberoptic measurements of substances originating in the small intestine, the presence of GERD can be confirmed with high accuracy even in patients with nonspecific symptomatology. Researchers have

identified three main causal factors for abnormally increased exposure of the esophageal mucosa to gastric contents. The most important of these causal factors is mechanical weakness or incompetence of the lower esophageal sphincter. The second causal factor is an abnormal pumping action of the esophagus due to impaired esophageal peristalsis, and the third is impaired gastric function^{16,21,33}. Gastric dysfunction may involve excessive gastric dilatation, impaired gastric emptying with damming back of gastric contents, or abnormally high gastric acid secretion.

Incompetence of the lower esophageal sphincter is the most common functional deficit in GERD patients. A number of different criteria for sphincter incompetence have been published in the literature^{16,33,88}. The DeMeester criteria used in our laboratory are outlined in **Tab. 1**^{27,88}.

Impaired esophageal peristalsis with abnormal contractions or an abnormal sequence of contractions can compromise the pumping ability of the esophagus, leading to changes detectable by manometry. Detailed cutoff values have been published elsewhere and are summarized in **Tab. 1**.

Criteria for incompetence of the lower esophageal sphincter

Total length	< 2 cm
Intra-abdominal length	< 1 cm
Sphincter pressure	< 6 mmHg

Criteria for impaired esophageal peristalsis

Abnormal morphology of contractions

Amplitude	> 180 mmHg
Amplitude	< 20 mmHg
Duration	> 7 s
Multiple peaks	
Repetitive	

Abnormal sequence of contractions

Simultaneous (progression > 20 cm/s) > 10% of primary contractions do not propagate down the esophagus (amplitude < 10 mmHg) > 10% of primary contractions are repetitive > 30% of primary contractions.

Tab. 1

Manometric criteria for abnormal esophageal motility.

4.0 The “Antireflux Barrier” and the Pathophysiology of Reflux

When the gastroesophageal junction is inspected endoscopically, it appears narrowed in relation to the overlying tubular esophagus, analogous to the finding on contrast radiographs. This high-pressure zone can be clearly identified by manometry. Hereafter it is referred to as the lower esophageal sphincter (LES).

The mechanisms that make the esophageal mucosa resistant to toxic substances in gastric reflux are not yet fully understood. It has been shown that the mucosa can resist proton penetration along a gradient of 5 pH units¹². The mucosa within the esophageal lumen secretes a mucous layer whose bicarbonate and water content are resistant to stomach acid. Additionally, salivary glands and the esophageal mucosa can increase bicarbonate ion secretion in response to an increased acid content in the esophageal lumen. The blood flow to the esophageal wall also plays a critical role in maintaining effective epithelial resistance⁶³.

For many years, functional abnormalities of the stomach were not recognized in the pathogenesis of GERD. Today we know that abnormalities of gastric secretion and motility may be solely responsible for reflux disease in some cases, but that they usually coexist with an incompetent LES³³.

Excessive or persistent secretion of gastric acid may cause increased acid exposure of both the gastric lumen and esophageal lumen. Acid is known to have a role in the pathogenesis of esophageal mucosal injury, but pepsin may also be involved. Several groups of authors have found significantly higher levels of gastric acid secretion and a markedly increased incidence of persistent gastric acidity in complicated reflux disease and in Barrett patients than in normal controls³³.

Antroduodenal motility disorders may lead to abnormal gastroduodenal reflux. With persistent incompetence of the LES, this may increase the toxicity of material that refluxes into the esophagus. Additionally, delayed gastric emptying may further increase the amount of material available for reflux through the incompetent LES. When gastric emptying is delayed in the presence of a competent sphincter, gastric dilatation may occur leading to temporary shortening of the sphincter and increased transient sphincter relaxations, resulting in increased gastroesophageal reflux.

Duodenogastric reflux is another physiologic phenomenon that is analogous to gastroesophageal reflux. When excessive, duodenogastric reflux can produce a mixture of acid, pepsin, pancreatic products, bile acids, and lysolecithin in the gastric lumen. The entry of this material into the esophagus can be very toxic to the esophageal mucosa. It is not surprising, then, that an increased incidence of duodenogastric reflux has been found in patients with peptic strictures and Barrett esophagus^{16, 25, 31, 33}.

In summary, GERD should be understood as a multifactorial process (**Fig. 4.1**).

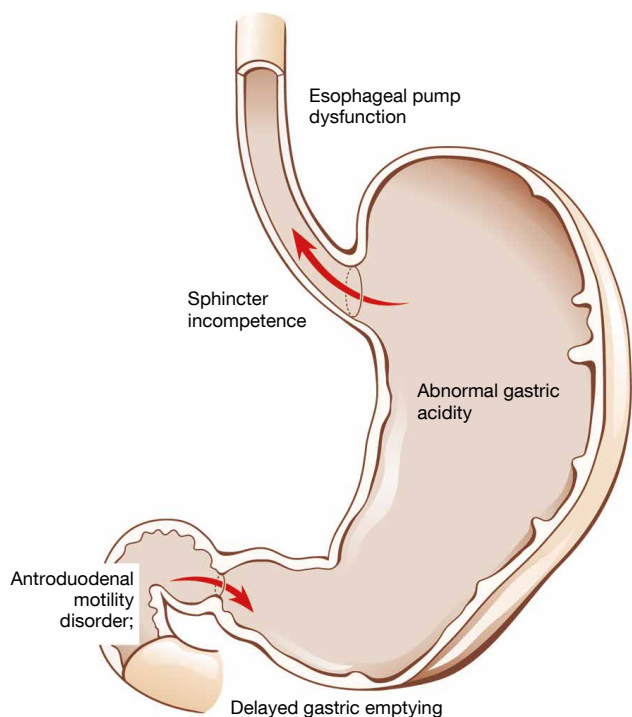


Fig. 4.1
Schematic representation of the multiple causes of gastroesophageal reflux disease.

The most frequent cause of the disease is mechanical incompetence of the LES, which occurs as an isolated condition in almost 50% of GERD patients. Abnormal esophageal peristalsis may be found in 14% of patients but is an isolated disorder in only 2% of cases. The resistance of the esophageal mucosa to harmful intraluminal agents is difficult to assess and is not routinely determined. The variety of possible gastric causes, which are involved in approximately 40% of GERD cases, compounds the difficulty of an accurate diagnostic evaluation. The most common accompanying component is persistent gastric acidity, which may occur as an isolated condition in almost 10% of cases and is combined with other causal factors in more than 25% of cases. It is widely agreed that more than one causal factor is involved, especially in patients with complicated reflux disease³³.

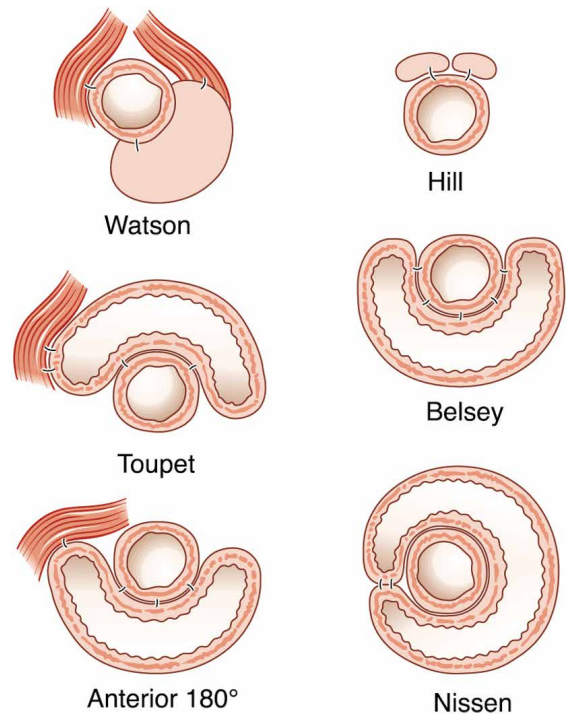


Fig. 5.1
Schematic overview of various antireflux operations. Wraps of varying extent illustrate the different options available for reinforcing the lower esophageal sphincter.

5.0 Surgical Treatment Concepts

As the pathophysiology of GERD and the central role of the LES became more clearly understood, various types of fundoplication procedure emerged as the preferred surgical treatment option (**Fig. 5.1**).

The Nissen fundoplication has traditionally been named for the surgeon that introduced it. It has undergone so many modifications, however, that the precise technique should always be specified in the reporting and analysis of results. A variety of different fundoplication techniques are known today (**Fig. 5.1**).

The Nissen fundoplication is still the most widely practiced antireflux operation on a worldwide scale. Unfortunately, errors of patient selection and operating technique have led to poor outcomes with the Nissen procedure. Persistent side effects such as dysphagia and gas bloat syndrome have been observed and are most commonly reported after a Nissen fundoplication^{2, 17, 21, 34, 52, 62, 68, 69}. For this reason, some authors have come to favor a partial fundoplication as an alternative to the Nissen complete wrap.

Tab. 2: Results of open antireflux operations

Type of operation	Author	Year	n	++*)	+*)	-*)
Nissen	Rossetti ⁶²	1973	590	88	8.0	10.0
Nissen	Polk ⁶¹	1976	312	86	4.0	9.0
Nissen	Siewert ⁶⁸	1978	116	89	7.0	10.0
Nissen	Ellis ²³	1984	82	92	10.0	5.0
Nissen	Donahue ²²	1985	77	87	5.0	4.0
Nissen	DeMeester ¹⁹	1986	100	90	6.0	14.0
Nissen	Siewert ⁶⁹	1987	148	86	—	11.0
Nissen	Shirazi ⁶⁷	1987	350	86	5.0	3.0
Nissen	Ackermann ²	1988	163	75	25.0	28.0
Nissen	Stipa ⁷⁹	1989	40	87	10.0	10.0
Belsey	Skinner ⁷²	1967	632	85	7.0	—
Belsey	Orringer ⁵⁵	1972	892	84	11.0	—
Belsey	Stipa ⁷⁹	1989	37	89	21.0	—
Belsey	Lerut ⁶¹	1990	117	89	10.0	2.0
Belsey	Wamsteker ⁶⁵	1990	75	87	4.0	4.0
Toupet	Thor ⁸¹	1989	19	95	5.0	—
Watson	Watson ⁸⁶	1991	89	82	< 10.0	2.0
Hill	Hill ³⁹	1967	154	90	< 2.0	—
Angelchik	Angelchik ⁴	1979	46	95	30.4	5.0
Angelchik	Kozarek ⁴⁸	1982	15	63	63.0	20.0
Angelchik	Gear ³⁸	1984	26	96	38.0	11.5
Angelchik	Starling ⁷⁷	1987	74	92	25.0	8.0
Angelchik	Siewert ⁷⁰	1988	32	78	31.0	15.6
Pexie	Brintnall ⁹	1961	78	81	—	3.8
Pexie	Borgeskov ⁸	1964	52	60	—	14.0
Pexie	Allison ³	1972	374	87	—	—

Tab. 2

*) ++ = Good and very good results (%)

+ = Recurrent or persistent reflux (%)

- = Dysphagia (or gas bloat)

Comparison of Open and Laparoscopic Surgery

Tab. 2 summarizes the results of open fundoplications based on prospective studies published between 1967 and 1994,^{13, 22, 38, 44, 55} before the introduction of laparoscopy surgery. Studies were selected that included at least 100 patients or had a follow-up period of at least 5 years. An analysis of these studies provides a grade III level of evidence for the endpoints of recurrent reflux, dysphagia, complications, and good and poor results. We find that during the period indicated, open surgery yielded a good or very good result in 85–95% of cases. The rate of recurrent reflux after a Nissen fundoplication ranged from 4% to 10% over a follow-up period of 5–20 years. None of the published studies on open partial fundoplication exceeded these results^{34, 36, 60}.

6.0 Indications for Antireflux Surgery

The indications for the surgical treatment of GERD depend on four main factors: the level of patient distress, complications of the disease, the underlying functional defect, and the general condition of the patient^{21, 34, 59}. The first priority is to relieve distress, although this is a subjective parameter. Because GERD is a benign disorder, improving the quality of life is the prime consideration in patient selection. The presence of medically refractory symptoms such as heartburn, regurgitation, or epigastric pain are definite indications for antireflux surgery.

A second factor in patient selection is an advanced form of the disease with associated causal functional deficits in the upper gastrointestinal tract, the need for increased medication doses, and complications of the reflux disease. The latter include persistent esophagitis, strictures, bleeding, ulcers, and the development of a

Barrett esophagus in response to reflux³¹. These cases require surgical therapy for the permanent prevention of reflux.

Patient selection criteria:

Esophagitis, sphincter incompetence, positive pH-metry, mixed reflux, volume reflux, respiratory symptoms, large hiatal hernia, increased dose of PPIs, persistence of typical complaints.

The third selection criterion, and an essential factor, is the general condition of the patient. Because GERD is a benign functional disorder, any significant postoperative morbidity or mortality would be catastrophic. Thus, if the patient is in a debilitated state, it is important to critically weigh the necessity and goal of the operation and the prospect for quality-of-life improvement against the risk of the procedure.

7.0 Nissen-DeMeester Technique of Laparoscopic Fundoplication

The Nissen fundoplication, in which a 360° fundic wrap is placed around the esophagus, has become the most popular antireflux procedure among surgeons since Nissen first described it in 1956. Based on experimental and clinical studies, many surgeons in Europe and the U.S., including the Chicago-based schools of *T. R. DeMeester* and *C. T. Bombeck*, have advocated a short, loose wrap called a “floppy Nissen” to prevent unpleasant side effects from the fundoplication^{17, 19, 21, 34}. The need to add a posterior hiatoplasty is controversial. The extent of fundic mobilization also varies among different surgeons.

The details of the *Nissen-DeMeester* technique of laparoscopic fundoplication^{17, 34} are described below.

The patient is placed on the operating table in the “French position” with the legs abducted. The foot of the table is lowered during the operation so that the abdominal fat and small and large bowel will sag downward, making it easier to explore the upper abdomen (**Fig. 7.1**). After the patient has been washed, prepped and draped, a Veress needle is introduced on the

midline approximately one-third up the line from the umbilicus to the xiphoid and a pneumoperitoneum is established, maintaining compliance with usual safety tests. A pressure of 10–14 mmHg is set on the Endoflator in adolescents and adults. A pressure of 6–8 mmHg is used in smaller children, depending on body size. A conical trocar is always inserted first. It is rotated into the abdomen rather forcibly introduced. With some experience, the surgeon will be able to develop a “tissue feel” indicating when the trocar has passed through the fascia. This can avoid trocar injuries even in patients whose bowel is close to the abdominal wall. Another option is an open approach to the abdominal cavity.

A 30° endoscope (**Fig. 7.2**) is recommended for these procedures so that the retroesophageal region and thoracic region will be easily accessible, even with changing trocar sites, during mobilization of the esophagus. **Figure 7.1** shows the recommended workplace organization and trocar placement for all necessary access ports.

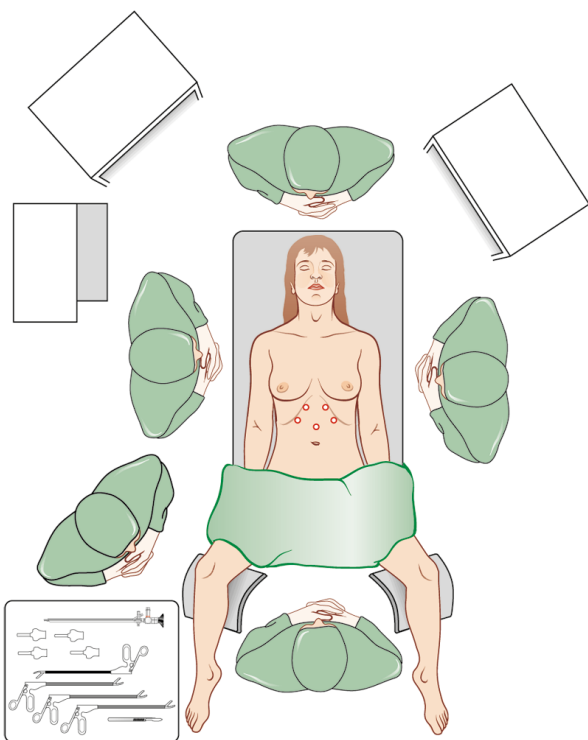


Fig. 7.1 Position of the operating team and arrangement of the equipment and instrument table. The trocar sites for laparoscopic fundoplication are shown.

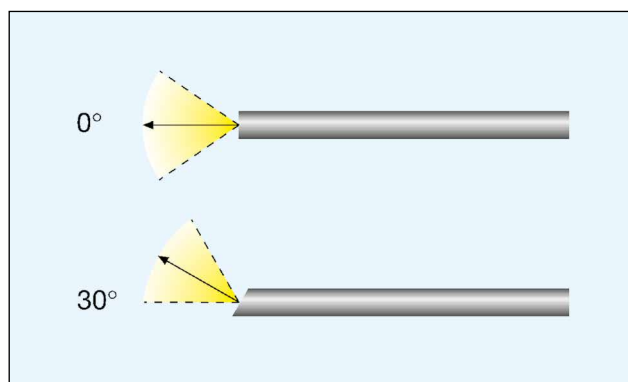


Fig. 7.2 A HOPKINS® rod-lens telescope with a 30° viewing angle is recommended for laparoscopic fundoplication.

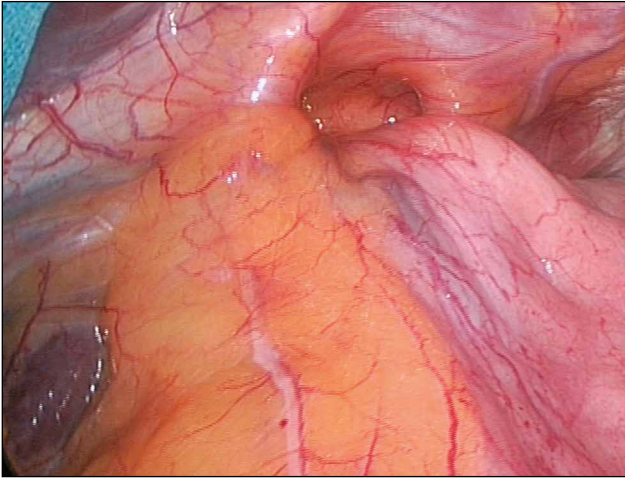
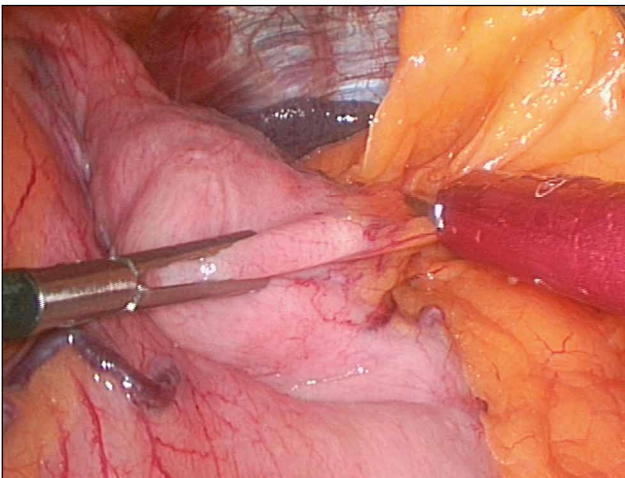


Fig. 7.3
Intraoperative view of the esophageal hiatus and hiatal hernia.

Additional 11-mm trocars are introduced into the upper abdomen under endoscopic vision (sites are shown in **Fig. 7.1**). A 13-mm trocar should be placed at the right lateral site if a large-caliber instrument will be used for liver retraction. The organ retractor is introduced through the right lateral port and is used to retract the left lobe of the liver. A grasping forceps is passed through the left lateral port to pull the gastric fundus downward and toward the left side. Initially the stomach and gastroesophageal junction should be carefully inspected, giving particular attention to the width of the hiatus (**Fig. 7.3**) and possible fixation of the cardia, and thus of the LES, within the thorax. These factors are of major importance in directing

the rest of the operation. In a 360° *Nissen* fundoplication, we favor complete mobilization of the fundus with division and occlusion of the short gastric vessels and posterior mobilization of the retroperitoneal structures so that a loose, tension-free wrap can be placed around the LES. This step is aided by passing a grasping forceps through the right paramedian site to place tension on the right side of the stomach. Another grasper is introduced on the left side to place tension on the gastrosplenic ligament. At this point a step-by-step dissection can be performed with an ultrasonic dissector introduced through the left paramedian port (**Figs. 7.4, 7.4.1**).



Figs. 7.4, 7.4.1
The greater curvature is mobilized with ultrasonic scissors.

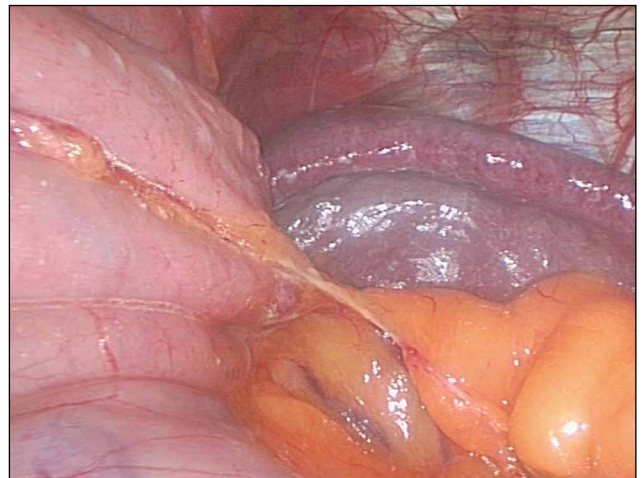


Fig. 7.4.1

Problems may arise if the gastrosplenic ligament is very short and the gastric fundus abuts the superior pole of the spleen, leaving very little room for dissection. It is essential at this stage to dissect the left crus of the diaphragm over its entire length (**Figs. 7.5–7.5.4**).

Figs. 7.5–7.5.4 ▶
Intraoperative appearance of the left crus of the diaphragm.

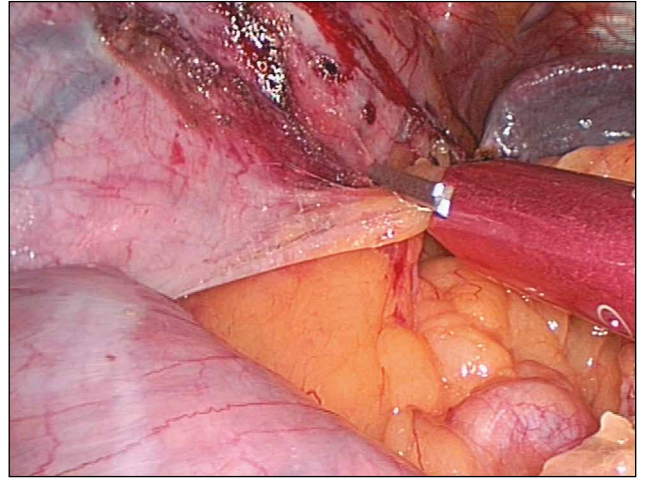


Fig. 7.5

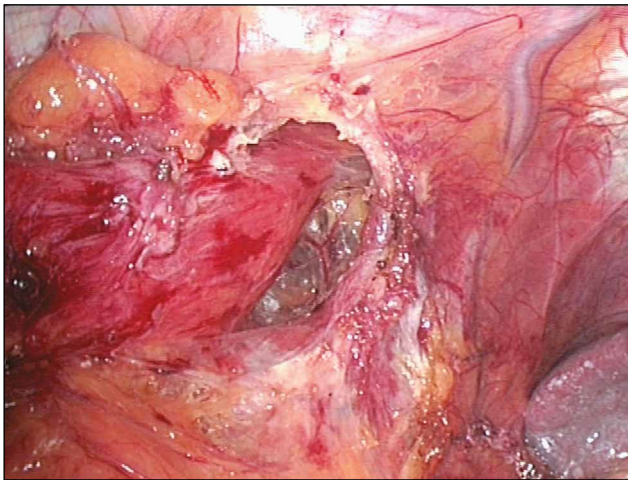


Fig. 7.5.1

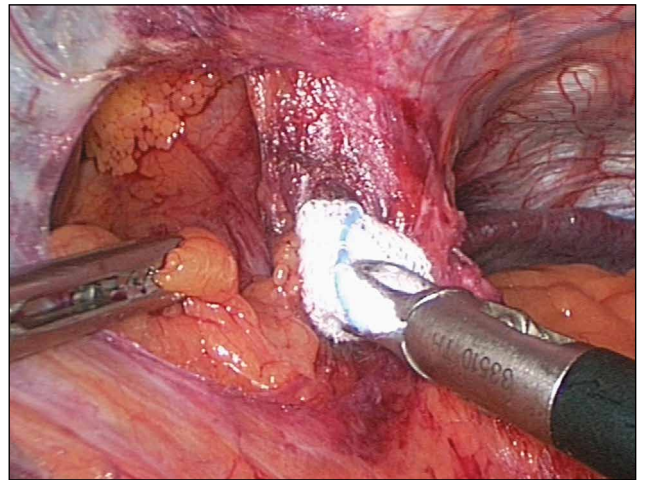


Fig. 7.5.2

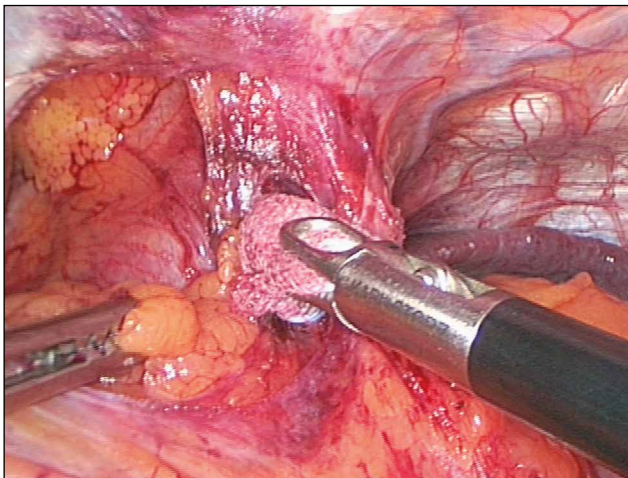


Fig. 7.5.3

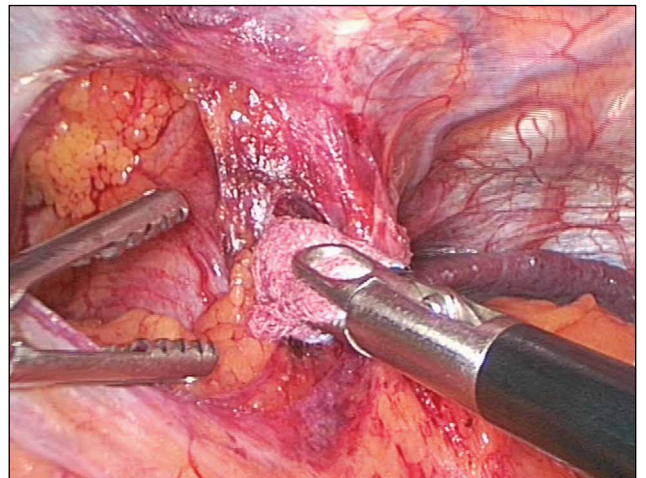


Fig. 7.5.4

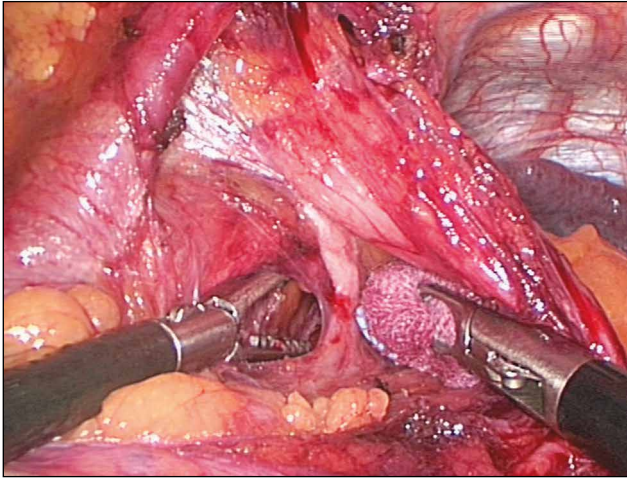


Fig. 7.6
Preparation of the retroesophageal window.

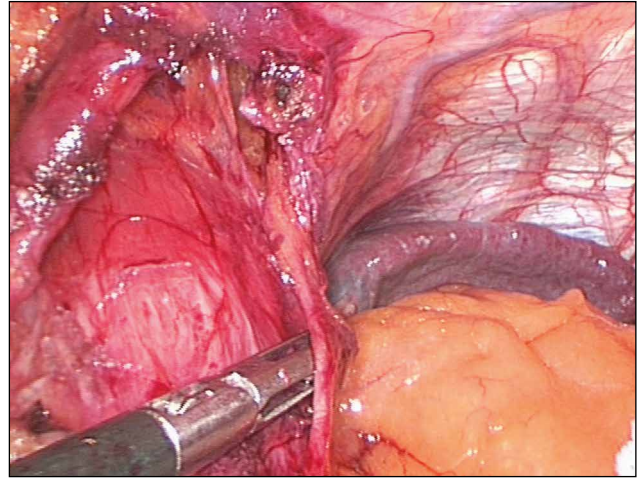


Fig. 7.7
The anterior vagal nerve branch is identified.

Working from right to left, the surgeon begins to dissect and free the hiatus by incision of the phrenoesophageal membrane just above the right crus (**Fig. 7.6**). To spare the vagal nerve branches to the liver and gallbladder, the dissection should begin as high as possible on the hiatal arch and proceed toward the right crus of the diaphragm. The caudate lobe of the liver can be identified on the left side of the field and, behind the retracted lobe, the vena cava.

As in open surgery, the dissection is performed with scissors, grasping forceps, and dissecting sponges. The main goal of the dissection at the gastroesophageal junction is to expose both crura of the diaphragm. A clean dissection of both crura will automatically

expose the esophagus as a thick, cordlike structure in the midline. The tissue band transmitting the left and anterior vagal nerve branches is identified (**Fig. 7.7**). After the right crus of the diaphragm has been completely freed superiorly and further dissection has been completed along the hiatal arch to the left crus of the diaphragm, the last fibrous attachments between the diaphragm crura and esophagus can generally be spread apart with gentle pressure from the grasper and a mounted sponge, providing clear, bloodless access to the lower mediastinum (**Fig. 7.8**).

It is not unusual to see the posterior vagal trunk on the vertebral column, on the aorta, or even closer to the esophagus (**Fig. 7.9**).

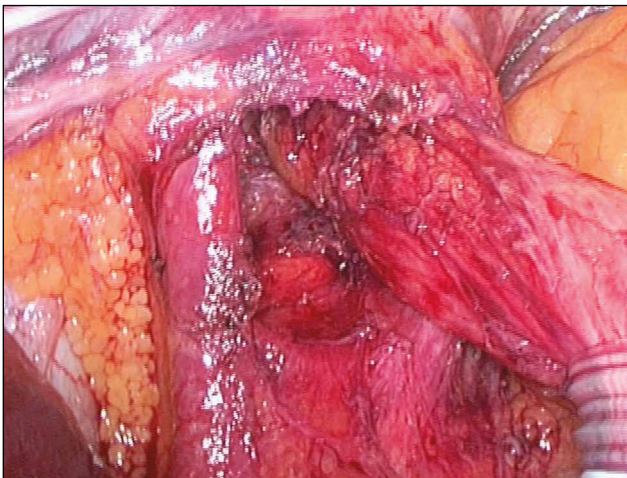


Fig. 7.8
Preparation and appearance of the retroesophageal window.

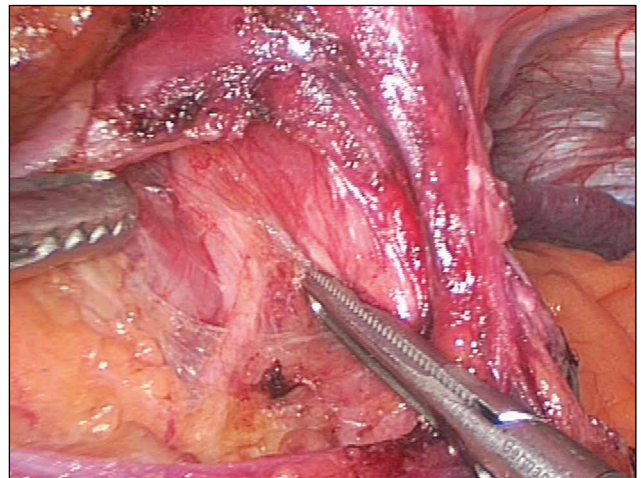
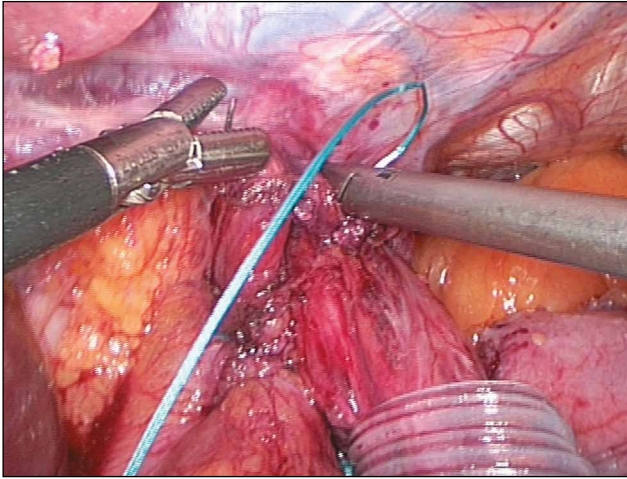


Fig. 7.9
The posterior vagal nerve branch is identified.



Figs. 7.10, 7.10.1
Anterior hiatoplasty.

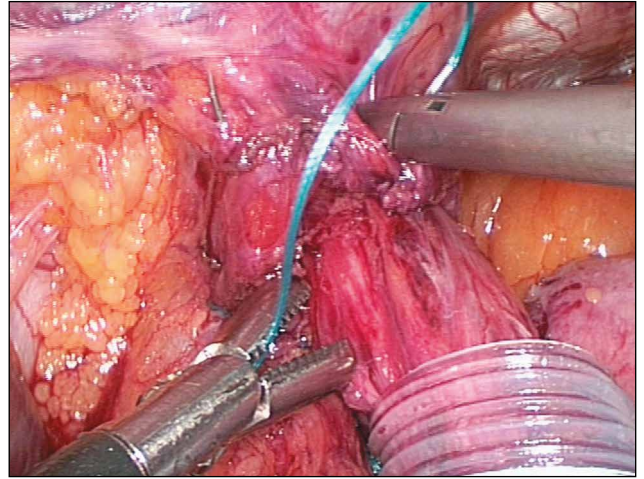
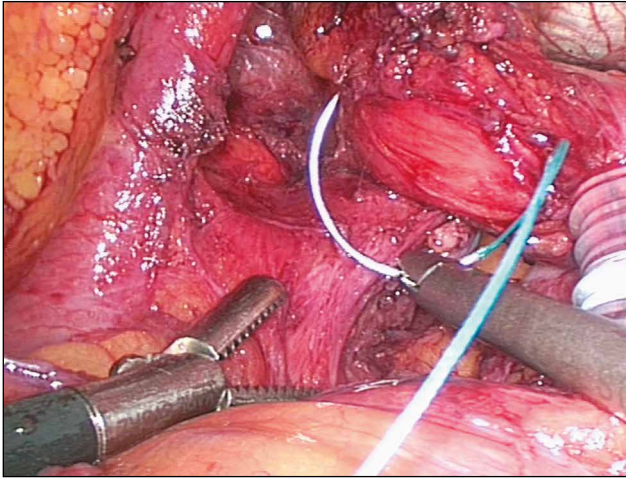


Fig. 7.10.1

It may be left alone if it is a good distance from the esophagus, but in most cases it is expedient to leave the nerve near the esophagus and snare it along with the esophagus. After mobilization has been completed in the lower mediastinum and the two vagus nerve branches have been safely exposed along with the diaphragm crus on the left side, a grasping forceps

can be passed behind the esophagus from right to left through the gastroesophageal window and advanced into the left upper abdomen to the splenic fossa to pick up a rubber tape, Penrose drain, or easy-flow drain for snaring the esophagus (**Figs. 7.10, 7.10.1**). Once in place, the snare can be used to manipulate the esophagus into any desired position.



Figs. 7.111–7.11.3
Posterior hiatoplasty.

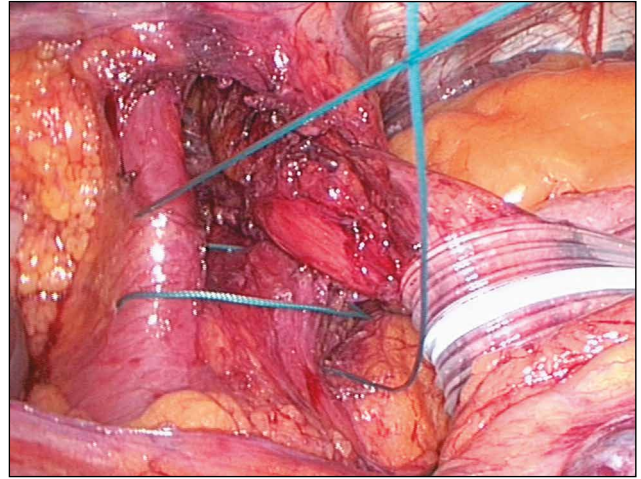


Fig. 7.11.1

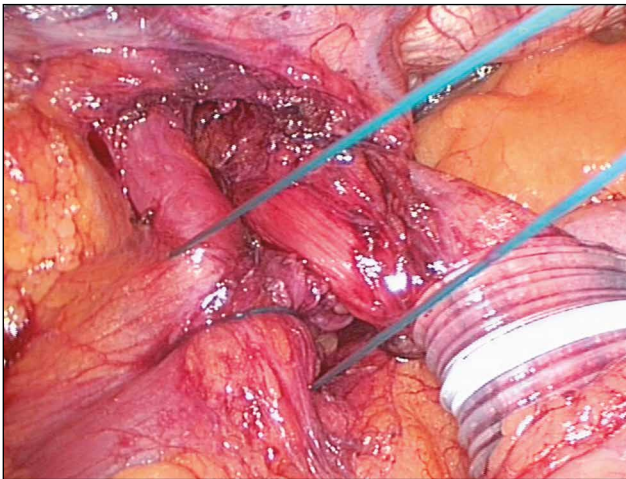


Fig. 7.11.2

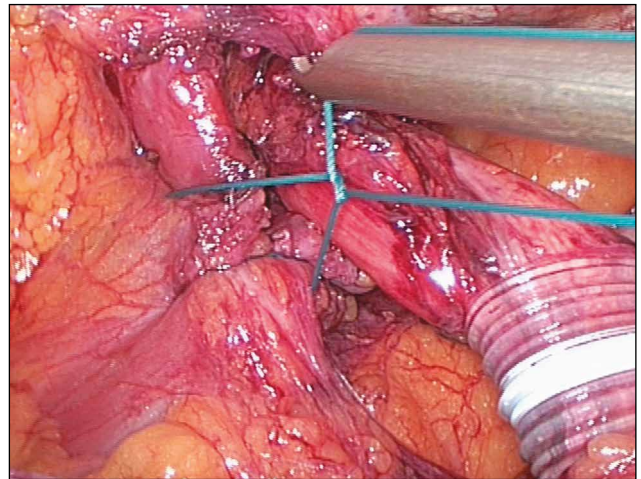


Fig. 7.11.3

The next step is mobilization of the distal esophagus (**Figs. 7.11–7.11.3**), allowing the entire lower esophageal sphincter to be advanced into the abdominal cavity.

After the completion of all dissection and mobilization, a posterior hiatoplasty is performed using two or three 0 or 2-0 nonabsorbable sutures (**Fig. 7.11**). The sutures can be tied with extracorporeal knots placed over the

right diaphragm crus while the esophagus is retracted to the left.

With a very wide hiatus, it is advisable to add an anterior suture. If the tissues are weak, the crural musculature is thin, or there is a significant residual gap at the hiatus, mesh should be added to ensure a successful repair.

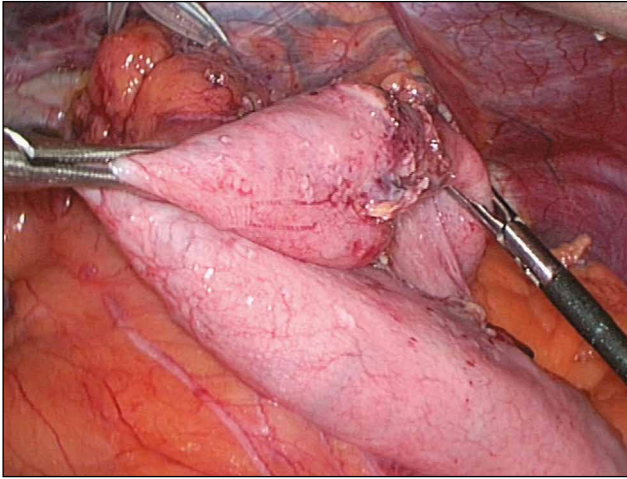


Fig. 7.12
The posterior and anterior fundic flaps for the fundoplication are identified.

For a 360° fundoplication, the fundus is completely mobilized. The posterior part of the fundus is passed behind the esophagus with a forceps and is grasped with a second forceps on the right side (**Fig. 7.12**). At this point the wrap is precisely tailored to the lower esophageal sphincter under optimum vision (**Fig. 7.13**). If the wrap is under tension, this means that the fundus

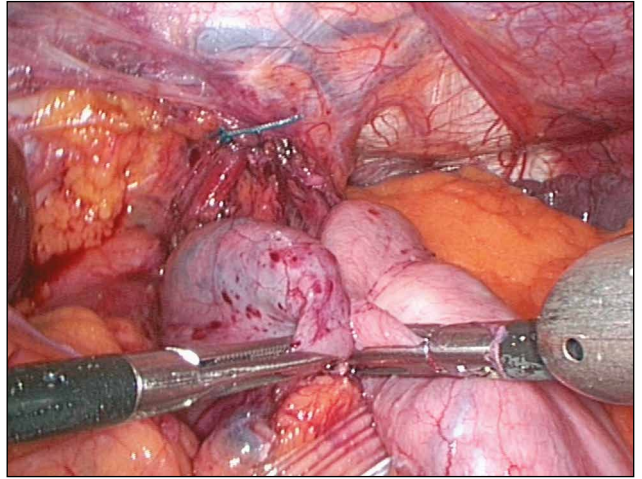
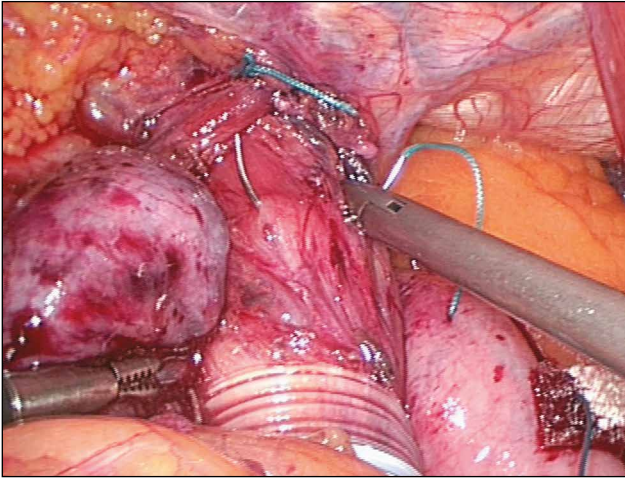


Fig. 7.13
The fundic wrap is fitted to the distal esophagus.

has not been adequately mobilized, and the tension should be relieved by additional mobilization of the fundus. The shortest possible tension-free wrap is then secured over the lower esophageal sphincter with 0 to 2-0 nonabsorbable sutures. As in the DeMeester “sandwich” technique, the sutures are tied over small underlays precut to a size of 1 x 0.5 cm.



Figs. 7.14–7.14.3
The Nissen fundoplication is secured with sutures.

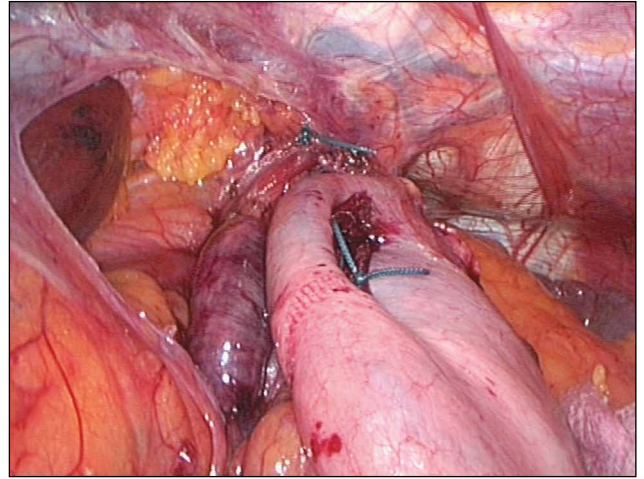


Fig. 7.14.1

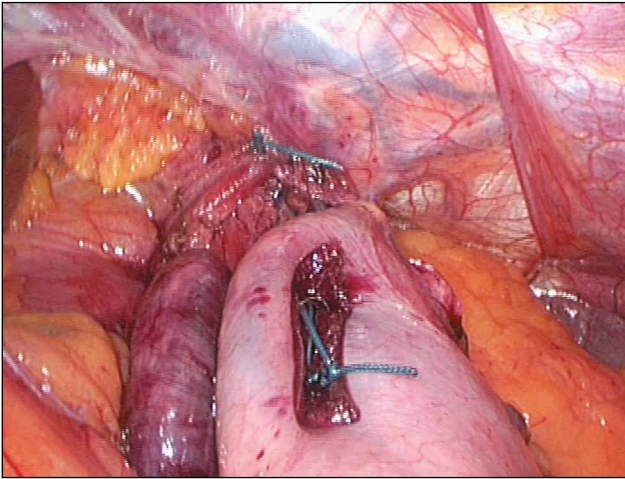


Fig. 7.14.2

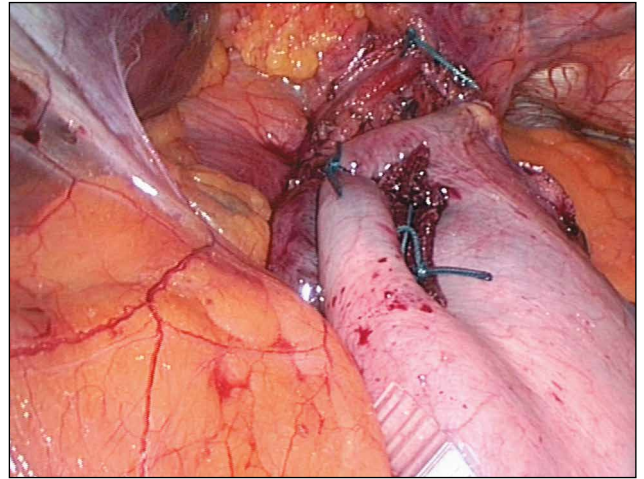


Fig. 7.14.3

During suture placement, a 40–60 Ch gastric tube is passed transorally into the cardia to function as a stent and reduce the risk of postoperative dysphagia. The large gastric tube is replaced at the end of the operation with a transnasal 18 Ch gastric tube.

8.0 Partial Fundoplications

Various modifications of partial fundoplication techniques have been described in the literature.

The most popular partial fundoplication at present is the Toupet fundoplication,⁸¹ which is described below. Other examples are the anterior 180° hemifundoplication (**Fig. 8.1**), the anterior Watson fundoplication, and additional modifications of the Toupet operation using a posterior 180° or 240° wrap (**Fig. 8.2**). Ordinarily the Toupet posterior partial fundoplication includes mobilization of the gastroesophageal junction and mobilization of the fundus. The preparatory dissection for a Toupet fundoplication is essentially the same

as for a Nissen fundoplication: When the fundus has been mobilized and the posterior fundic flap has been pulled through to the right side after completion of the posterior hiato-plasty, the posterior fundic flap is sutured to the right lateral aspect of the esophagus with three nonabsorbable sutures.

The anterior fundic flap is similarly sutured to the left lateral aspect of the esophagus, carefully preserving the anterior vagal nerve branch. Several authors have modified this stage of the operation, but we question the advisability of fixing the fundus to the diaphragm crura with one or two posterior sutures.

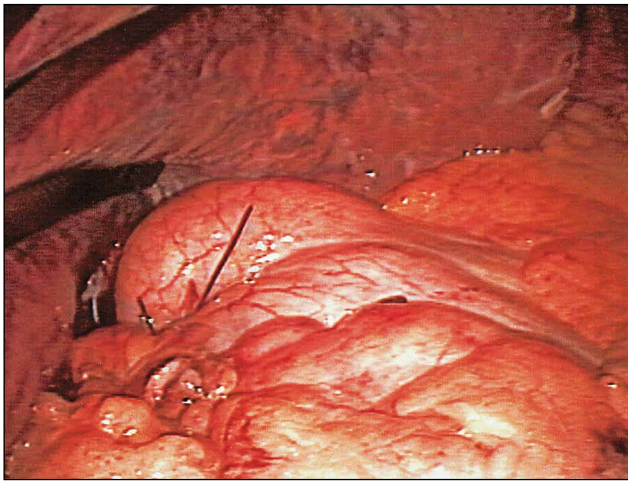


Fig. 8.1
Anterior 180° hemifundoplication.

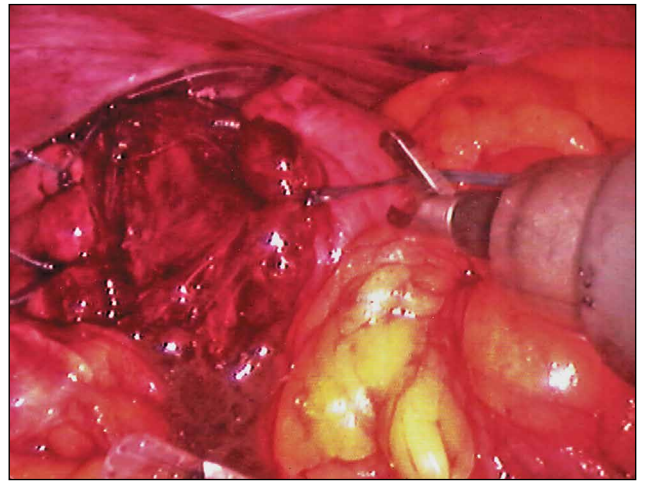


Fig. 8.2
Toupet operation with a 240° posterior wrap.

9.0 Selecting the Optimum Procedure

Taking the first five years as the average learning period for laparoscopic fundoplication, **Tab. 3** shows an overview of the largest prospective studies published between 1993 and 2000^{11, 21, 22, 25, 26, 29, 54, 65}.

Only studies with case numbers greater than 100 are included in this review. Good results were achieved in 90–97% of the cases, with a recurrent reflux rate of 1–9%. These studies cannot be compared with one another due to varying definitions of complications and problems such as postoperative dysphagia. But by surveying these studies, we can gain a reasonably good idea of the quality of the results. The studies on laparoscopic partial fundoplication report similarly high success rates of up to 92%, although isolated reports in patients with severe reflux disease indicate less favorable results²⁷.

Initial comparisons between open and laparoscopic surgery were published in the mid-1990s. These studies consistently reported a shorter recovery period after laparoscopic surgery due to less access trauma. The criteria for these comparative analyses were varied and often related to postoperative analgesic use, the earlier resumption of peristalsis allowing earlier enteric nutrition, and a better cosmetic result^{3, 54}. Reports on comparisons of hospital stay and cost-benefit calculations indicate a more favorable result for laparoscopic surgery, particularly in the U.S. Given past reimbursement policies in the German health care system, however, these advantages could neither be determined nor fully utilized because reimbursement was tied to the length of hospital stay. In this respect the cost-benefit ratios could not be transferred from one system to the other.

Valid comparisons can be based upon the measurement of objective parameters such as immune factors and respiratory function^{48, 68}. In one nonrandomized comparison, immunologic analyses of interleukin 6, HLA-DR monocytes, and other factors were compared in patients who had undergone open fundoplication and laparoscopic Nissen fundoplication. Postoperative tests showed a rapid and significant rise of IL-6 cytokines

Tab. 3: Results of laparoscopic antireflux operations

Author	Year	n	Con- version	Compli- cations %	++*)	+*)	-*)
Weerts ⁸⁸	1993	132	0	7.5	94.0	?	5.4
Cuschieri ¹⁴	1993	116	0.9	14.0	85.0	?	3.7
Bittner ⁷	1994	35	14.2	25.7	87.0	4.0	24.0
Cadiere ¹⁰	1994	80	3.8	5.0	94.3	0	3.7
Champault	1994	940	6.2	5.0	—	—	—
Jamieson ⁴⁵	1994	155	12.2	7.1	92.1	1.8	6.1
Collard ¹³	1994	39	5.1	7.6	86.3	2.7	11.0
Hinder ⁴¹	1994	198	4.0	6.0	88.0	8.0	9.0
Watson ⁸⁷	1994	33	11.0	11.0	—	—	—
Feussner ²⁹	1994	18	16.0	22.0	89.0	0	11.0
Fuchs ³²	1994	35	6.0	19.0	91.0	3.0	0
Peters ⁵⁸	1995	32	0	17.6	84.0	3.0	9.4
Dallemagne et al. ¹⁵	1996	240	< 2	3.5	96.0	2.0	2.0
Fuchs et al. (ESGARS)	1997	221	< 5	14.0	93.0	2.0	2.0
Perdikis et al. ⁵⁷	1997	2453	5.8	7.3	92.0	3.5	5.5
Pointner et al. ⁶⁰	1998	196	< 3	4.0	95.0	1.5	4.5

Tab. 3

*) ++ = Good and very good results (%)

+ = Recurrent or persistent reflux (%)

- = Dysphagia (or gas bloat)

and a significant fall of HLA-DR monocytes as indicators of immune status. A significant long-term rise was documented in the open-surgery group of patients compared with the laparoscopic group. Similarly, *Olsen et al.* found significant differences in various pulmonary function parameters between open and laparoscopic surgery⁴⁸. All the patients had postoperative limitation of respiratory function, but the impairment was significantly less pronounced in the laparoscopic group than in the open-surgery group. These results point to a potentially better initial status of patients who have undergone laparoscopic surgery.

Only randomized studies can determine the actual clinical relevance of these findings with regard to patient well-being and the length of follow-up care. Six randomized studies have been published based on a direct comparison of conventional and laparoscopic antireflux operations. Their results are summarized in **Tab. 4**.

Past studies of open funduplications in large clinical series documented superior longevity of the Nissen wrap and a slightly higher failure rate with a partial wrap. These findings were initially confirmed in a randomized

study, but further randomized comparisons of both open procedures during the past 10 years were unable to confirm these results (**Tab. 5**)^{12, 33, 36, 58, 59, 63, 76}. The latest randomized studies of laparoscopic operations indicate similar success rates. None of the studies showed significant differences between partial and complete fundoplication with regard to postoperative morbidity, recurrent reflux rate, or dysphagia. Overall, a tendency toward greater gas bloat and flatulence was noted in patients who underwent a Nissen fundoplication.

Tab. 4: Overview of randomized studies comparing open and laparoscopy surgery: perioperative data

Author Recruitment	Random groups	Morbidity N (%)	Operating time (min.)	Hospital stay (days)	Absence from work (days)
Laine 1992-95	Open 55	7 (13)	57	6.4	37
	Lap 55	3 (8)	88	3.2	15
Heikkine 1995-96	Open 20	8 (25)	74	5.5	44
	Lap 22	3 (14)	98	3.0	21
Bais 1997-98	Open 46	9 (17)	–	–	–
	Lap 57	5 (9)	–	–	–
Luostarinen 1994-95	Open 15	0	30	5.0	30
	Lap 13	1 (8)	105	4.0	17
Chrysos 1993-98	Open 50	38 (76)	83	5.9	–
	Lap 56	12 (21)	77	2.4	–
Nilsson 1995-97	Open 30	0	109	3.0	32
	Lap 30	0	148	3.0	27

Tab. 5: Overview of randomized studies comparing open and laparoscopy surgery: follow-up care

Author Recruitment	Random groups	Patients in follow-up care	Recurrent reflux N (%)	Dysphagia N (%)	Bloating N (%)	Reoperation N (%)
Laine 1992-95	Open 55	30 (12mo)	3 (10)	4 (13)	2 (7)	0
	Lap 55	18 (12mo)	0	0	3 (17)	0
Heikkinen 1995-96	Open 20	19 (24mo)	2 (11)	11 (58)	10 (53)	0
	Lap 22	19 (24mo)	0	9 (48)	–	0
Bais 1997-98	Open 46	46 (3mo)	1 (2)	0	–	0
	Lap 57	57 (3mo)	2 (4)	7 (12)*	–	4 (7)
Luostarinen 1994-95	Open 15	13 (17mo)	0	6 (46)	–	0
	Lap 13	13 (17mo)	0	4 (31)	–	1 (8)
Chrysos 1993-98	Open 50	50 (12mo)	1 (2)	2 (4)	3 (6)	0
	Lap 56	56 (12mo)	2 (4)	2 (4)	0	0
Nilsson 1995-97	Open 30	23 (60mo)	4 (17)	5 (22)	10 (43)	1 (4)
	Lap 30	17 (60mo)	2 (12)	7 (41)	8 (47)	2 (12)

Tab. 6: Randomized comparison of complete and partial fundoplication

Author Year	Method N	Morbidity	Follow-up care, months	Recurrent reflux	Dysphagia
DeMeester 1974	Open				
	Nissen 15	2/15	84	0/4	0/4
	Hil 15	3/15	84	2/4	1/4
Thor 1989	Open				
	Nissen 12	3/12	60	5/12	4/12
	Toupe 19	4/19	60	3/19	2/19
Lundell 1996	Open				
	Nissen 65	0/65	36	3/62	6/62
	Toupet 72	3/72	36	4/71	12/71
Walker 1992	Open				
	Nissen 26	8/26	13	0/26	2/26
	Lind 26	12/26	13	0/26	4/26
Laws 1997	Laparoscopic				
	Nissen 23	0/23	27	1/23	0/23
	Toupet 16	2/16	27	0/16	0/16
Watson 2004	Laparoscopic			Score 1-10	Score 1-10
	Nissen 53	8/53	60	1.8	2.6
	Do 53	10/53	60	1.9	1.5 ns
Zornig 2001	Laparoscopic				
	Nissen100	–	6	18/93	30 %
	Toupet100	–	6	10/95	11 %

Comparison: Division of the Short Gastric Vessels

The advantage or disadvantage of dividing the short gastric vessels is a controversial issue among surgeons and has been investigated in several randomized studies. Some of these studies employed different definitions for fundic mobilization, and this definitely limits our ability to interpret the study results. The data from the randomized studies is summarized in **Tab. 6**^{4, 5, 6, 39, 40, 62}. No significant differences were reported in terms of postoperative morbidity, dysphagia, or recurrent reflux rate.

10.0 Discussion

More than a decade after the introduction of minimally invasive surgical technique, considerable data have been published on the advantages of laparoscopic surgery over conventional surgery. These data require a differentiated analysis, however. Available studies show that the laparoscopic technique leads to a significant reduction of perioperative morbidity and postoperative hospital stay and less immune compromise compared with open antireflux surgery. The long-term functional result is similar after both types of surgery when the operations are performed at an experienced center.

The “experience” factor appears to be very important in interpreting study data. When we look at the data from randomized studies and many large prospective studies

done at experienced centers, we find a remarkable zero mortality rate for both open and laparoscopic operations. Conventional antireflux surgery has traditionally been known to have a mortality rate of 0.3–0.6%. Recent surveys report mortality rates of 0.008–0.2% for laparoscopic antireflux surgery and 0.2–0.8% for open surgery. These data underscore the importance of the learning curve for open operations and especially for the laparoscopic technique.

Experience in at least 50 operations is necessary in order to deal with small and moderate problems that arise during the procedure and avoid intraoperative injuries⁹². These data have also been supported by other studies.

Finally, the importance of experience in laparoscopic surgery is confirmed by the problems that arose in one randomized study. So many cases of postoperative dysphagia occurred in the laparoscopic treatment arm that the study had to be terminated¹. The cause was the inadequate experience and low case numbers of the participating surgeons (fewer than three cases per surgeon per year). A detailed analysis of the data also reveals significant differences in the results of different randomized studies. Reports on morbidity range from 0% to 76%, recurrent reflux rate from 0% to 17%, and dysphagia from 0% to 58%. These discrepancies relate partly to the definition of the endpoints and their assessment, but they also result from differences in the experience of the participating surgeons with a particular technique. This would also explain the dramatic differences in dysphagia rates that have been reported by different authors (e.g., 4% versus 58%).

Experience with laparoscopic fundoplication is a very important criterion that has a major impact on morbidity and functional outcomes. The debate over the superiority of a partial or complete wrap is many decades old. For many years the partial wrap was thought to have relatively poor longevity, causing many

surgeons to view it only as a compromise solution (“tailored approach”) in patients with esophageal motility disorders¹⁹. Currently available randomized studies have clearly shown that complete and partial fundoplication are equivalent in their long-term results^{36,69}. Hence, both techniques may be used concurrently and this is being done at many centers.

After the publication of these results, it was interesting to note that some surgeons decided to use only the laparoscopic Nissen fundoplication while others selected the Toupet technique as their standard procedure. Remarkably, the reoperation rate was found to be significantly lower after a partial fundoplication than after the Nissen fundoplication in a recently published detailed analysis. This raises the question of how experienced the surgeons were with a particular technique and whether differences in experience can influence the results.

Hardly any technical variant is as controversial, or debated as passionately, as the mobilization of the gastric fundus. Randomized studies cannot fully resolve this debate because the technique and extent of mobilization may vary greatly among different authors. Further studies are needed to clarify this issue.

11.0 References

1. ABRAHAMSSON H, RUTH M, SANDBERG N, OLBE LC: Lower esophageal sphincter characteristics and esophageal acid exposure following partial or 360° fundoplication: results of a prospective, randomized, clinical study. *World J Surg* 1991, 15: 115–120
2. ACKERMANN C, MARGRETH L, MÜLLER C et al.: Das Langzeitresultat nach Fundoplicatio. *Schweiz Med Wochenschr* 1988, 118: 774
3. ALLISON PR: Hiatus hernia; a 20 year retrospective survey. *Ann Surg* 1973, 178: 273–276
4. ANGELCHICK JP, COHEN R: A new surgical procedure for the treatment of gastroesophageal reflux and hiatal hernia. *Surg Gynecol Obstet* 1979, 148: 246–248
5. ARMSTRONG D, BLUM AL, SAVARY M: Reflux disease and Barrett's esophagus. *Endoscopy* 1992, 24: 9–17
6. BAIS JE, BARTELSMAN JF, BONJER HJ, CUESTA MA, GO PM, KLINGENBERG-KNOL, EC VAN LANSCHOT JJB, NADORP JH, SMOUT AJ, VAN DER GRAAF Y (The Netherlands Antireflux Surgery Study Group): Laparoscopic or conventional Nissen fundoplication for gastroesophageal reflux disease: randomized clinical trial. *Lancet* 2000, 355: 170–174
7. BECHI P, PUCCIANI F, BALDINI F et al.: Long-term ambulatory enterogastric reflux monitoring – validation of a new fiberoptic technique. *Dig Dis Sci* 1993, 38: 1297–1306
8. BITTNER HB, MEYERS WC, BRAZER SR, PAPPAR TN: Laparoscopic Nissen fundoplication: Operative results and short-term-follow-up. *Am J Surg* 1994; 167: 193–200
9. BLOMQUIST A, LÖNROTH H, DALENBÄCK J, RUTH M, WIKLUND I, LUNDELL L: Quality of Life Assessment after Laparoscopic and Open Fundoplication. *Scand J Gastroenterol* 1996, 31: 1052–1058
10. BORGESKOV S, PEDERSEN OT, FREDERIKSEN T: Oesophageal hiatal hernia: a radiological follow-up. *Thorax* 1964, 19: 327–331
11. BRINTNALL ES, BLOME RA, TIDRICK RT: Late results of hiatus hernia repair. *Am J Surg* 1961, 01: 159–163
12. CADIÈRE GB, HOUBEN JJ, BRUYNS J, HIMPENS J, PANZER JM, GELIN M: Laparoscopic Nissen fundoplicatio: technique and preliminary results. *Br J Surg* 1994; 81: 400–403
13. CHAMPAULT G: Reflux gastro-oesophagien. Traitement par laparoscopie. 940 cas experience française. *Ann Chir* 1994, 48: 159–164
14. CHRYSOS E, TSIAOUSSIS J, ATHANASAKIS E, VASSILAKIS J, XYNOS E: Laparoscopic versus open approach for Nissen fundoplication. *Surg Endosc* 2002, 16: 1679–1684
15. CHUNG RSK, MAGRI J, DENBESTEN L (1975) Hydrogen iron transport in the rabbit esophagus. *Am J Physiol* 229: 496–502
16. COLLARD JM, DE GHELDERE CA, DE KOCK M et al.: Laparoscopic antireflux surgery: What is real progress? *Ann Surg* 1994, 220: 146–154
17. CUSCHIERI A, HUNTER J, WOLFE B et al.: Multicenter prospective evaluation of laparoscopic antireflux surgery. Preliminary report. *Surg Endosc* 1993, 7: 505–510.
18. DALLEMAGNE B, WEERTS JM, JEHAES C, MARKIEWICZ S: Causes of failures of laparoscopic antireflux operations. *Surg Endosc* 1996, 10: 305–310
19. DeMEESTER TR: Definition, detection and pathophysiology of gastroesophageal reflux disease. In: DeMeester TR, Matthews HR (ed): *International Trends in General Thoracic Surgery. Benign Esophageal Disease*, St. Louis: C.V. Mosby Company, 1987, Vol. 3 : 99–127.
20. DeMEESTER TR, BONAVINA L, ALBERTUCCI M: Nissen fundoplication for gastroesophageal reflux disease. Evaluation of primary repair in 100 consecutive patients. *Ann Surg* 1986, 204: 19
21. DeMEESTER TR, JOHNSON LF, KENT AH: Evaluation of current operation for the prevention of gastroesophageal reflux. *Ann Surg* 1974, 180: 511
22. DONAHUE PE, SAMELSON S, NYHUS LM, BOMBECK CT: The Floppy Nissen Fundoplication. *Arch Surg*. 1985; 120: A 1440.
23. ELLIS FH, CROZIER RE: Reflux control by fundoplication: A clinical and manometric assessment of the Nissen operation. *Ann. Thorac. Surg.* 1984; 38: 387.
24. EYPASCH E, NEUGEBAUER E, FISCHER F, TROIDL H: Laparoscopic antireflux surgery for gastroesophageal reflux disease (GERD). Results of a consensus development conference. *Surg Endoscopy* 1997, 11: 413–426

25. EYRE-BROOK IA, CODLING BW, GEAR MWL: Results of a prospective randomized trial of the Angelchik prosthesis and of a consecutive series of 119 patients. *Br J Surg* 1993, 80: 602–604
26. FEIN M, FUCHS K-H, BOHRER T et al: Fiberoptic technique for 24 hour bile reflux monitoring – standards and normal values for gastric monitoring. *Dig Dis Sci* 1996, 41: 216–225
27. FEIN M: Magen-pH-Metrie. In: *Gastrointestinale Funktionsstörungen*. Hrsg.: K-H Fuchs, H.J. Stein, A. Thiede, Springer Verlag Heidelberg 1996, S. 131–150
28. FEIN M, IRELAND AP, RITTER MP, PETERS JH, HAGEN JA, BREMNER CG, DeMEESTER TR: Duodenogastric Reflux Potentiates the Injurious Effects of Gastroesophageal Reflux. *J Gastrointest Surg* 1997; :27–33.
29. FEUSSNER H, STEIN HJ: Minimally invasive esophageal surgery. *Laparoscopic antireflux surgery and cardiomyotomy*. *Dis Esoph* 1994; 7: 17–23
30. FRANTZIDES CT, MADAN AK, CARLSON MA, STAVROPOULOS GP: A prospective randomized trial of laparoscopic polytetrafluoroethylene (PTFE) patch repair vs simple cruroplasty for large hiatal hernia. *Arch Surg* 2002, 137(6): 649–652
31. FREYS SM: Stationäre Oesophagusmanometrie. In: *Gastrointestinale Funktionsstörungen*. Hrsg.: KH Fuchs, H.J. Stein, A. Thiede, Springer Verlag Heidelberg 1996, S. 24–46
32. FUCHS KH, DEMEESTER TR, ALBERTUCCI M: Specificity and sensitivity of objective diagnosis of gastroesophageal reflux disease. *Surgery* 1987; 102: 575–580.
33. FUCHS KH, DeMEESTER TR, HINDER RA et al.: Computerized identification of pathological duodenogastric reflux using 24-hour gastric pH monitoring. *Ann Surg* 1991, 213: 13–20
34. FUCHS KH, ENGEMANN R, THIEDE A (1994) Chirurgische oder konservative Therapie des Barrett-Oesophagus? *Chirurg* 65: 88–95
35. FUCHS K-H, HEIMBUCHER J, FREYS SM, THIEDE A: Management of gastro-esophageal reflux disease 1995. Tailored concept of anti-reflux operations. *Dis Esoph* 7: 250–254
36. FUCHS K-H, FREYS SM, HEIMBUCHER J et al.: Pathophysiologic spectrum in patients with gastroesophageal reflux disease in a surgical GI function laboratory. *Dis Esoph* 1995, 8: 211–217
37. FUCHS KH, FEUSSNER H, BONAVINA L, COLLARD JM, COOSEMANS W for the European Study Group for Antireflux Surgery: Current status and trends in laparoscopic antireflux surgery: results of a consensus meeting. *Endoscopy* 1997, 29: 298–308
38. GEAR MWL, GILLISON WE, DOWLING BL: Randomized prospective trial of the Angelchik antireflux prosthesis. *Br J Surg* 1984, 71: 681–683
39. GOTLEY DC, SMITHERS BM, RHODES M, MENZIES B, BRANICKI FJ, NATHANSON: Laparoscopic Nissen fundoplication – 200 consecutive cases. *Gut* 1996; 38: 487–91
40. HEIKKINEN TJ, HAKIPURO K, BRINGMAN S: Comparison of laparoscopic and open Nissen fundoplication 2 years after operation. A prospective randomized trial. *Surg Endosc* 2000; 355: 170–174
41. HILL LD: An effective operation for hiatal hernia: an eight year appraisal. *Ann Surg* 1967, 166: 681–692
42. HILL ADK, WALSH TN, BOLGER CM, BYRNE PJ, HENNESSY TPJ: Randomized controlled trial comparing Nissen fundoplication and the Angelchik prosthesis. *Br J Surg* 1994, 81: 72–74
43. HINDER RA, FILIPI CJ, WETSCHER G, NEARY P, DEMEESTER TR, PERDIKS G: Laparoscopic Nissen fundoplication is an effective treatment for gastroesophageal reflux disease. *Ann Surg* 1994, 220: 472–483
44. HINDER RA, PERDIKIS G, KLINGLER PJ, DEVALUT KR: The surgical option for gastroesophageal reflux disease. *Am J Med* 1997, 103: 144–148 S
45. HOHLE KD, KÜMMERLE F: Eine neue Methode zur Behandlung von Hiatushernien durch Fundopexie und Hiatusengung. *Langenbecks Arch Chir (Suppl)* 1972, 225
46. HORVATH KD, JOBE BA, HERRON DM, SWANSTRÖM LL: Laparoscopic Toupet fundoplication is an inadequate procedure for patients with severe reflux disease. *J Gastrointest Surg* 1999; 3: 583–91
47. HÜTTL TP, HOHLE M, MEYER G, SCHILDBERG FW: Antirefluxchirurgie in Deutschland *Chirurg* 2002; 73(5): 451–461
48. HUNTER JG, SWANSTROM L, WARING JP: Dysphagia after laparoscopic antireflux surgery. *Ann Surg* 1996, 224: 51–57
49. JAMIESON CG, WATSON DI, BRITTEN-JONES R et al: Laparoscopic Nissen fundoplication. *Ann Surg* 1994, 220: 137–145

50. JAMIESON J, STEIN HJ, DEMEESTER TR et al: Ambulatory 24-hour esophageal pH-monitoring: normal values, optimal thresholds, specificity, sensitivity, and reproducibility. *Am J Gastroenterol* 1992, 87: 1102-1111
51. JANSSEN IMC, GOUMA DJ, KLEMENTSCHITSCH P, van der HEYDE MN, OBERTOP H: Prospective randomized comparison of teres cardiopexy and Nissen fundoplication in the surgical therapy of gastro-oesophageal reflux disease. *Br J Surg* 1993, 80: 875-878
52. KLAUSER AG, SCHINDLBECK NE, MÜLLER-LISSNER SA: Symptoms in gastro-oesophageal reflux disease. *Lancet* 1990; 335: 205
53. KLINKENBERG-KNOL EC, FESTEN HPM, JANSEN JBMJ et al.: Long-term treatment with omeprazole for refractory reflux esophagitis: efficacy and safety. *Ann Intern Med* 1994, 121: 161-167
54. KMIOT WA, KIRBY RM, AKINOLA D, TEMPLE JG: Prospective randomized trial of Nissen fundoplication and Angelchik prosthesis in the surgical treatment of medically refractory gastro-oesophageal reflux disease. *Br J Surg* 1991, 78: 1181-1184
55. KOZAREK RA, PHELPS JE, GROBE JL, et al: Assessment of a prosthetic device for the correction of esophageal reflux. *Gastroenterology* 1982, 82: 1106
56. KUNATH U: Die Biomechanik der unteren Speiseröhre. Stuttgart. G. Thieme Verlag 1979
57. LAGERGREN J, BERGSTRÖM R, LINDGREN A, NYRÉN O: Symptomatic gastroesophageal reflux as a risk factor for esophageal adenocarcinoma. *New Engl J Med* 1999, 340: 825-831
58. LAINE S, RANTALA A, GULLICHSEN R, OVASKA J: Laparoscopic vs conventional Nissen fundoplication. A prospective randomized study. *Surg Endosc* 1997, 11: 441-444
59. LAWS HL, CLEMENTS RH, SWILLIE CM: A randomized, prospective comparison of the Nissen fundoplication versus the Toupet fundoplication for gastroesophageal reflux disease. *Ann Surg* 1997 Jun; 225(6): 647-53; discussion 654
60. LERUT T, COOSEMANS W, CHRISTIAEUS R et al.: The Belsey Mark IV antireflux, procedure: Indications and long-term results. In: Little AG, Ferguson MK, Skinner DP: *Diseases of the Esophagus Vol. II, Benigne Diseases*, Futura Publishing Company, Inc., Mount Kisco, New York, 1990; 181-188
61. LUNDELL L, ABRAHAMSSON H, RUTH M, RYDBERG L, LÖNRO H, OLBIE L: Long-term results of a prospective randomized comparison of total fundic wrap (Nissen-Rossetti) or semifundoplication (Toupet) for gastro-esophageal reflux. *Br J Surg* 1996, 83: 830-835
62. LUNDELL L, ABRAHAMSSON H, RUTH M, SANDBERG L, OLBE L: Lower esophageal sphincter characteristics and esophageal acid exposure following partial or 360° fundoplication: Results of a prospective, randomized, clinical study. *World J Surg* 1991, 15: 115-121
63. LUOSTARINEN MES, ISOLAURI JO: Randomized trial to study the effect of fundic mobilization on long-term results of Nissen fundoplication. *Br J Surg* 1999, 86: 614-618
64. MEYERS RL, ORLANDO RC: In vivo bicarbonate secretion by human esophagus. *Gastroenterology* 1992; 103: 1174-1178
65. NILSSON G, WENNER J, LARSSON S, JOHNSON F: Randomized clinical trial of laparoscopic versus open fundoplication for gastro-oesophageal reflux. *Br J Surg* 2004, 91(5): 552-559
66. NILSSON G, LARSSON S, JOHNSON F: Randomized clinical trial of laparoscopic versus open fundoplication: evaluation of psychological well-being and changes in everyday life from a patient perspective. *Scand J Gastroenterol.* 2002 Apr; 37(4): 385-91
67. NISSEN R: Eine einfache Operation zur Beeinflussung der Refluxoesophagitis. *Schweiz Med Wochenschr* 1956, 86: 590
68. O'BOYLE CJ, WATSON DI: Division of short gastric vessels at laparoscopic Nissen fundoplication: a prospective double-blind randomized trial with 5-year follow-up. *Ann Surg.* 2002 Feb; 235(2): 165-70
69. OLSEN MF, JOSEFSON K, DALENBACK J, LUNDELL L, LONROTH H: Respiratory function after laparoscopic and open fundoplication. *Eur J Surg* 1997, 163(9): 667-672 *Adv Surg Tech*
70. ORRINGER MB, SKINNER DB, BELSEY RHR: Longterm results of the Mark IV operation for hiatal hernia and analyses of recurrences and their treatment. *J. Thorac. Cardiovasc. Surg.* 1972; 63: 25-31.
71. PEILLON C, MANOUVRIER JL, LABRECHE J, KAEFFER N, DENIS P: Testart. Should the vagus nerves be isolated from the fundoplication wrap? A prospective study. *Arch Surg.* 1994 Aug; 129(8): 814-8

72. PERA M, CAMERON AJ, TRASTEK VF, CARPENTER HA, ZINSMEISTER AR: Increasing incidence of adenocarcinoma of the esophagus and esophagogastric junction. *Gastroenterology* 104 (1993); 510–513.
73. PERDIKIS G, HINDER RA, LUND RJ, RAISER F, KATADA N: Laparoscopic Nissen fundoplication: Where do we stand? *Surg Laparoscopy & Endoscopy* 1997, 7: 117–21
74. PETERS JH, KAUER W, DeMEESTER TR, IRELAND AP, BREMNER CG: Optimal surgical therapy for gastroesophageal reflux disease requires a tailored surgical approach. *J Thorac Cardiovasc Surg* 1995; 7: 141–146
75. PETERS JH, DEMEESTER TR, CROOKES P, OBERG STEFAN, DE VOS SHOOP M, HAGEN JA, BREMNER CG: The Treatment of Gastroesophageal Reflux Disease With Laparoscopic Nissen Fundoplication. *Ann Surg* 1998; Vol 228 No 1: 40–50
76. POINTNER R: Laparoskopische Antirefluxchirurgie – Erfahrungsbericht aus Österreich. *Zentralbl Chir* 1998; 123: 1148–1151
77. POLK HC: Fundoplication for reflux esophagitis: misadventures with the operation of choice. *Ann Surg* 1976, 183: 645
78. ROSSETTI M, HELL K: Fundoplication for the treatment of gastroesophageal reflux in hiatal hernia. *World J Surg* 1977, 1: 439–444
79. RUTH M, BAKE B, SANDBERG N, OLBE L, LUNDELL L: Pulmonary function in gastroesophageal reflux disease – effect of reflux control by fundoplication. *Dis Esoph* 1994; 7: 268–275
80. RYDBERG L, RUTH M, ABRAHAMSSON H, LUNDELL L: Tailoring antireflux surgery: a randomized clinical trial. *World J Surg* 1999, 23: 612–618
81. SAVARY M, MILLER G: (1978) The esophagus. In: *Handbook and Atlas of Endoscopy*. Hrsg.: SA Gasman, Solothurn, Switzerland
82. SEGOL P, HAY JM, POTTIER D: Traitement chirurgical du reflux gastro-oesophagien: quelle intervention choisir: Nissen, Toupet ou Lortat-Jacob? Essai multicentrique par tirage au sort. *Association Universitaire de Recherche en Chirurgie. Gastroenterol Clin Biol* 1989, 13: 873–879
83. SHIRAZI SS, SCHULZE K, SCOPER RT: Long-term follow-up for treatment of complicated chronic reflux esophagitis. *Arch Surg* 1987, 122: 548–552
84. SIEWERT R: Operative Behandlung der Refluxkrankheit. *Chirurg* 1978; 49: 137–145.
85. SIEWERT JR, FEUSSNER H: Early and long-term results of antireflux surgery. A critical look. In *Baillière's Clinical Gastroenterology*. Oxford, W.B. Saunders, 1987; 821–842.
86. SIEWERT JR, FEUSSNER H: Die Angelchick-Prothese – Zwischenbilanz und Wertung. *Z Gastroenterol* 1988, 26: 421
87. SIEWERT JR, FEUSSNER H., WALKER SJ: Fundoplication: How to do it? Periesophageal wrapping as a therapeutic principal in gastro-esophageal reflux prevention. *World J. Surg.* 1992, 16: 326–334.
88. SKINNER DB, BELSEY RHR: Surgical management of esophageal reflux with hiatus hernia: Long-term results with 1030 cases. *J. Thorac. Cardiovasc. Surg.* 1967; 53: 33–54.
89. SKINNER DB, KLEMENTSCHITSCH P, LITTLE AG, DEMEESTER TR, BELSEY RRH: Assessment of failed antireflux repairs. In: *Esophageal disorders: Pathophysiology and therapy*. Hrsg.: TR DeMeester, DB Skinner, Raven Press, New York, 1985; 303–313.
90. SONNENBERG A (1981) Epidemiologie und Spontanverlauf der Refluxkrankheit. In: *Refluxtherapie. Gastrooesophageale Refluxkrankheit: Konservative und operative Therapie*. Hrsg.: AL Blum, Zürich und JR Siewert, Göttingen, Springer, Berlin, S. 85
91. SPECHLER SJ and the department of veterans affairs gastroesophageal reflux disease study group: Comparison of Medical and Surgical Therapy for Complicated Gastroesophageal Reflux Disease in Veterans. *N Engl J Med*, 1992, Vol. 326, 12: 786–792.
92. STARLING JR: Evaluation of the Angelchik prosthesis. In: *Reflux esophagitis and the Angelchik prosthesis*, editor JR Starling. Elsevier Science Publishing Co, Inc. 1987, 93–102
93. STELZNER A, LIERSE W (1978) Weitere Untersuchungen zur Insuffizienz des Dehnverschlusses der terminalen Speiseröhre. *Langebecks Arch Chir* 436: 177
94. STIPA S, FEGIZ G, IASCONE C, PAOLINI A, MORALDI A, DE MARCHI C, CHIECO PA: Belsey and Nissen Operations for Gastroesophageal Reflux. *Ann Surg* 1989; 210: 583–589.
95. STUART RC, DAWSON K, KEELING P, BYRNE PJ, HENNESSY TP: A prospective randomized trial of Angelchik prosthesis versus Nissen fundoplication. *Br J Surg* 1989, 76: 86–89

96. SWANSTRÖM LL, HUNTER JG: Laparoscopic Partial Fundoplication. In: Minimally Invasive Surgery of the Foregut. Hrsg.: JH Peters, TR DeMeester QMP St Louis 1994; S. 159-75
97. THOR , KBA, SILANDER T: A Long-Term Randomized Prospective Trial of the Nissen Procedure Versus a Modified Toupet Technique. *Ann Surg* 1989; S. 719
98. TOUPET A: Technique d'oesophago-gastroplastie avec phrénogastropexie appliquée dans la cure radicale des hernies hiatales et comme complément de l'opération d'Heller dans les cardiospasmes. *Mem Acad Chir* 1963, 89: 394
99. VIGNERI S, TERMINI R, LEANDRO G, BADALAMENTI S, PANTALENA M, SAVARINO V, DI MARIO F, BATTAGLIA G, MELA GS, PILOTTO A: A comparison of five maintenance therapies for reflux eophagitis. *N Engl J Med* 1995, 333: 1106-111
100. WALKER SJ, HOLT S, SANDERSON CJ, STODDARD CJ: Comparison of Nisson total and oesophageal reflux. *Br J Surg* 1992; 79:410
101. WAMSTEKER H, LAGERBERG MA: The Belsey Mark-IV procedure in gastro-esophageal reflux and hiatal hernia. *The Netherlands J. Surg.* 1990; 42: 9-13.
102. WATSON A, JENKINSON LR, BALL CS et al.: A more physiological alternative to total fundoplication for the surgical correction of resistant gastro-oesophageal reflux. *Br J Surg* 1991, 78: 1088-1094.
103. WATSON DI, REED MWR, JOHNSON AG, STODDARD CJ: Laparoscopic fundoplication for gastro-esophageal reflux. *Ann Roy Coll Surg Engl* 1994; 4: 264-268
104. WATSON DI, BAIGRIE RJ, JAMIESON GG: A learning curve for laparoscopic fundoplication. Definable, avoidable, or a waste of time? *Ann Surg* 1996; 224: 198-203
105. WATSON DI, JAMIESON GG, DEVITT PG, KENNEDY JA, ELLIS T, ACKROYD R, LAFULLARDE T, GAME PA: A prospective randomized trial of laparoscopic Nissen fundoplication anterior vs posterior hiatal repair. *Arch Surg* 2001, 136(7): 745-751
106. WATSON DI, JAMIESON GG, LUDEMANN R, GAME PA, DEVITT PG: Laparoscopic total versus anterior 180 degree fundoplication - Five year follow-up of a prospective randomised trial. *Dis Eso* 2004; 17(suppl 1), A 81,8
107. WEERTS JM, DALLEMAGNE B, HAMOIR E et al: Laparoscopic fundoplication for gastro-esophageal reflux. *Ann Roy Coll Surg Engl* 1993; 4: 264-268
108. WETSCHER GJ, GLASER K, WIESCHEMEYER T, GADENSTÄTTER M: Tailored Antireflux Surgery for Gastroesophageal Reflux Disease: Effectiveness and Risk of Postoperative Dysphagia. *World J Surg* 1997; 21: 605-10
109. ZIEREN J, JACOBI CA, WENGER FA, VOLK HD, MULLER JM: Fundoplication: a model for immunologic aspects of laparoscopic and conventional surgery. *J Laparoendosc Adv Surg Tech A*, 2000; 10(1): 35-40
110. ZORNIG C, STRATE U, FIBBE C, EMMERMANN A, LAYER P: Nissen vs Toupet laparoscopic fundoplication. *Surg Endosc.* 2002 May; 16(5): 758-66

Instrument Set for Laparoscopic Fundoplication in the Treatment of Gastroesophageal Reflux Disease

Telescopes, Operating Instruments and Accessories

Recommended Set for Laparoscopic Gastric Surgery


(Laparoscopic Fundoplication, Gastric Banding etc.)

26003BA	HOPKINS® Forward-Oblique Telescope 30° , enlarged view, diameter 10 mm, length 31 cm, autoclavable , fiber optic light transmission incorporated, color code: red	37113A	Handle , pistol grip, with clamping valve, for suction and irrigation, autoclavable
26003AE	EndoCAMEleon® HOPKINS® Telescope , diameter 10 mm, length 32 cm, autoclavable , variable direction of view from 0° – 120°, adjustment knob for selecting the desired direction of view, fiber optic light transmission incorporated, color code: gold	031218-10	Tubing Set , with two puncture cannulas, for single use, sterile, package of 10, for use with Handles 37112 A (straight) and 37113 A (pistol grip) in combination with KARL STORZ HAMOU® ENDOMAT® 26331009-1
30103MC	3 x Trocar , with conical tip, with insufflation stopcock, size 11 cm, working length 10.5 cm, color code: green, including: Cannula , without valve Trocar only Multifunctional Valve	031219-10	Tubing Set , with two puncture cannulas, for single use, sterile, package of 10, for use with Handles 37112 A (straight) and 37113 A (pistol grip) in combination with KARL STORZ ENDOMAT® LC
30160MC	2 x Trocar , with conical tip, insufflation stopcock, size 6 mm, working length 10.5 cm, color code: black, including: Cannula , without valve Trocar only Multifunctional Valve	37360LH	Suction and Irrigation Tube , with lateral holes, size 5 mm, length 36 cm, for use with suction and irrigation handles
30140DB	Reduction Sleeve , reusable, instrument diameter 5 mm, trocar cannula outer diameter 11 mm, color code: green	30775UF	Coagulation and Dissection Electrode , L-shaped, with connector pin for unipolar coagulation, size 5 mm, length 36 cm
30141DB	Reducer , 11/5 mm	30775UFE	Exchangeable Electrode Tip , L-shaped, autoclavable, package of 6
30623GB	Retractor for Gastric Banding , size 10 mm, length 36 cm	26005M	Unipolar High Frequency Cord , with 5 mm plug, length 300 cm, for AUTOCON® II 400 SCB system (111, 115, 122, 125), AUTOCON® II 200, AUTOCON® II 80, KARL STORZ AUTOCON® system (50, 200, 350) and Erbe type ICC
30623U	CUSCHIERI Retractor , size 5 mm, length 36 cm	26176LE	Bipolar High Frequency Cord , for AUTOCON® II 400 SCB system (111, 113, 115, 122, 125), AUTOCON® II 200, AUTOCON® II 80, KARL STORZ Coagulator 26021 B/C/D, 860021 B/C/D, 27810 B/C/D, 28810 B/C/D, AUTOCON® series (50, 200, 350), Erbe-Coagulator, T and ICC series, length 300 cm
33333AF	CLICKLINE® Grasping Forceps , rotating, dismantling, without connector pin for unipolar coagulation, with LUER-Lock irrigation connector for cleaning, double action jaws, atraumatic, fenestrated, size 5 mm, length 36 cm	38651CS	RoBi® Grasping Forceps , CLERMONT-FERRAND Model, rotating, dismantling, with connector pin for bipolar coagulation, single action jaws, narrow jaws, for fine dissection, grasping and bipolar coagulation of fine structures, size 5 mm, length 36 cm
33344MM	CLICKLINE® MOURET Dissecting and Grasping Forceps , rotating, atraumatic, fenestrated, with slender, long and curved jaws, single action jaws, size 5 mm, length 36 cm	38651ON	RoBi® Grasping Forceps , CLERMONT-FERRAND model, rotating, dismantling, with connector pin for bipolar coagulation, with fine atraumatic serration, fenestrated jaws, double action jaws, size 5 mm, length 36 cm
33344AB	CLICKLINE® Grasping Forceps , rotating, atraumatic, distally toothed, round jaws, slender, delicate grasping, single action jaws, size 5 mm, length 36 cm	38651MD	RoBi® KELLY Grasping Forceps , CLERMONT-FERRAND model, rotating, dismantling, with connector pin for bipolar coagulation, suitable for dissection, double action jaws, size 5 mm, length 36 cm
33533BLS	CLICKLINE® BABCOCK Grasping Forceps , rotating, dismantling, without connector pin for unipolar coagulation, with irrigation connection for cleaning, double action jaws, rounded, long, size 10 mm, length 36 cm	30173FAR	KOH Macro Needle Holder , dismantling, with LUER-Lock irrigation connector for cleaning, single action jaws, straight jaws, with tungsten carbide inserts, with axial handle, disengageable ratchet, ratchet position right, size 5 mm, length 33 cm
32540PT	Surgical Sponge Holder , self-retaining, size 10 mm, length 30 cm	26596SK	KÖCKERLING Knot Tier , for extracorporeal knotting, size 5 mm, length 36 cm
34351MW	CLICKLINE® Scissors , rotating, dismantling, insulated, with connector pin for unipolar coagulation, with LUER-Lock irrigation connector for cleaning, double action jaws, serrated, curved, conical, size 5 mm, length 36 cm	30444LR	Clip Applicator , dismantling, rotating, size 10 mm, length 36 cm
34310MW	CLICKLINE® Scissors Insert , for scissors, double action jaws, serrated, curved, conical, size 5 mm, length 36 cm	30460AL	PILLING-WECK Titanium Clip , medium-large, box with 16 sterile cartridges, 10 clips each
34361EK	CLICKLINE® Hook Scissors , rotating, dismantling, without connector pin for unipolar coagulation, with LUER-Lock connector for cleaning, single action jaws, tips of jaws not crossing, size 5 mm, length 36 cm		

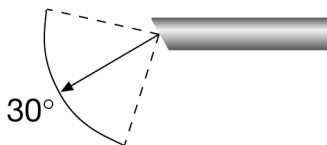
HOPKINS® Forward-Oblique Telescope 30°

diameter 10 mm, length 31 cm

diameter 5 mm, length 29 cm

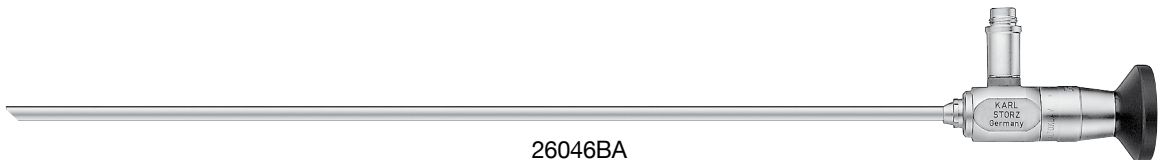

26003BA

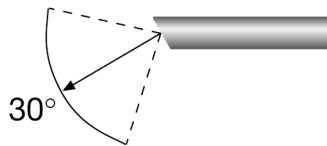


26003BA

HOPKINS® Forward-Oblique Telescope 30°,
enlarged view, diameter 10 mm, length 31 cm,
autoclavable,
fiber optic light transmission incorporated,
color code: red



26046BA

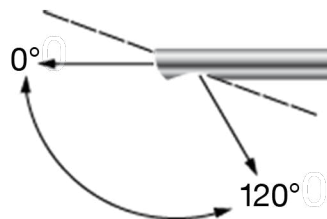


26046BA

HOPKINS® Forward-Oblique Telescope 30°,
enlarged view, diameter 5 mm, length 29 cm,
autoclavable,
fiber optic light transmission incorporated,
color code: red

EndoCAMEleon HOPKINS® Telescope

26003AE




26003AE

EndoCAMEleon HOPKINS® Telescope,
diameter 10 mm, length 32 cm,
autoclavable,
variable direction of view from 0° – 120°,
adjustment knob for selecting the desired direction of view,
fiber optic light transmission incorporated,
color code: gold

Trocars and Accessoires

size 6 and 11 mm



- 30103 MC **Trocar**, with conical tip, with insufflation stopcock, size 11 mm, working length 10.5 cm, color code: green, including:
Cannula, without valve
Trocar only
Multifunctional Valve



- 30160 MC **Trocar**, with conical tip, insufflation stopcock, size 6 mm, working length 10.5 cm, color code: black, including:
Cannula, without valve
Trocar only
Multifunctional Valve



- 30140 DB **Reduction Sleeve**, reusable, instrument diameter 5 mm, trocar cannula outer diameter 11 mm, color code: green



- 30141 DB **Reducer**, 11/5 mm


Scissors

**CLICKLINE® – rotating, dismantling,
with and without connector pin for unipolar coagulation
size 5 mm, trocar size 6 mm**

Working Length	 Handle 33151	
30 cm		
36 cm		
43 cm		


Single / Double-action jaws:

Working Insert No.	Catalog number for the complete instrument	
34210MW	34251MW	34261MW
34310MW	34351MW	34361MW
34410MW	34451MW	34461MW



CLICKLINE® Scissors**, double action jaws, serrated, curved, conical
| 15 |

34210EK	34251EK	34261EK
34310EK	34351EK	34361EK
34410EK	34451EK	34461EK



CLICKLINE® Hook Scissors, single action jaws, tips of jaws not crossing
| 9 |

****)** **CLICKLINE® Scissors** Inserts are available in attractively-priced sets of 12.
Please add the letter “P” to the order number, e.g. 34310MWP.

Please note:

For **CLICKLINE®** instruments only the **individual component parts** are numbered. The catalog number for the **complete instrument** is not on the instrument. Instruments with **insulated handles** with connector pin for unipolar coagulation, are shown against the **red background**, instruments with **handles without connector pin** for unipolar coagulation are shown against the **blue background**. The colour **green** indicates the inserts.

Dissecting and Grasping Forceps

CLICKLINE® – rotating, dismantling, insulated, with connector pin for unipolar coagulation
size 5 mm, trocar size 6 mm

Working Length				
30 cm	Handle 33151	Handle 33152	Handle 33153	Handle 33156
36 cm				
43 cm				

Double-action jaws

Working Insert No.	Catalog number of the complete instrument			
33210ML	33251ML	33252ML	33253ML	33256ML
33310ML	33351ML	33352ML	33353ML	33356ML
33410ML	33451ML	33452ML	33453ML	33456ML



— 22 —

CLICKLINE® Dissecting and Grasping Forceps, long

33210AF	33251AF	33252AF	33253AF	33256AF
33310AF	33351AF	33352AF	33353AF	33356AF
33410AF	33451AF	33452AF	33453AF	33456AF



— 24 —

CLICKLINE® Grasping Forceps, atraumatic, fenestrated

33310DF	33351DF	33352DF	33353DF	33356DF
33410DF	33451DF	33452DF	33453DF	33456DF



— 17 —

CLICKLINE® Dissecting and Grasping Forceps, atraumatic

Ein Maulteil beweglich:

33210ON	33251ON	33252ON	33253ON	33256ON
33310ON	33351ON	33352ON	33353ON	33356ON
33410ON	33451ON	33452ON	33453ON	33456ON



— 26 —

CLICKLINE® Grasping Forceps, with fine atraumatic serration, fenestrated

Please note:

For **CLICKLINE®** instruments only the **individual component parts** are numbered. The catalog number for the **complete instrument** is not on the instrument. Instruments with **insulated handles with connector pin** for unipolar coagulation, are shown against the **red** background. The colour **green** indicates the inserts.

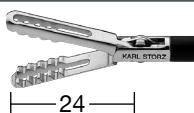Dissecting and Grasping Forceps

**CLICKLINE® – rotating, dismantling,
without connector pin for unipolar coagulation
size 5 mm, trocar size 6 mm**

Working Length				
30 cm	Handle 33161	Handle 33132	Handle 33133	Handle 33144
36 cm				
43 cm				


Double-action jaws:

Working Insert No.	Catalog number of the complete instrument			
33210AF	33261AF	33232AF	33233AF	33244AF
33310AF	33361AF	33332AF	33333AF	33344AF
33410AF	33461AF	33432AF	33433AF	33444AF



CLICKLINE® Grasping Forceps, atraumatic, fenestrated

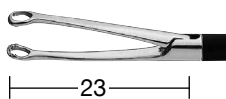
33310MM	33361MM	33332MM	33333MM	33344MM
---------	---------	---------	---------	---------



CLICKLINE® MOURET Dissecting and Grasping Forceps, with slender curved jaws, large reservoir


Single-action jaws:

33310AB	33361AB	33332AB	33333AB	33344AB
---------	---------	---------	---------	---------



CLICKLINE® MOURET Grasping Forceps, atraumatic, fenestrated, round jaws, slender

33210ON	33261ON	33232ON	33233ON	33244ON
33310ON	33361ON	33332ON	33333ON	33344ON
33410ON	33461ON	33432ON	33433ON	33444ON




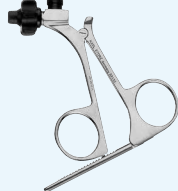

CLICKLINE® Grasping Forceps, with fine atraumatic serration, fenestrated

Please note:


For **CLICKLINE®** instruments only the **individual component parts** are numbered. The catalog number for the **complete instrument** is not on the instrument. Instruments with **insulated handles with connector pin** for unipolar coagulation, are shown against the **red** background. The colour **green** indicates the inserts.

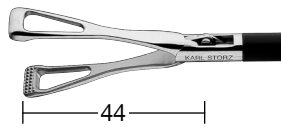
Grasping Forceps

**CLICKLINE® – rotating, dismantling,
without connector pin for unipolar coagulation
size 10 mm, trocar size 11 mm**

Working Length			
36 cm	Handle 33161	Handle 33132	Handle 33133

Double-action jaws:

Working Insert No.	Catalog number for the complete instrument		
33510BLS	33561BLS	33532BLS	33533BLS
 <p>CLICKLINE® BABCOCK Grasping Forceps, double action jaws, rounded</p> <p>33</p>			

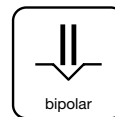
33510DU	33561DU	33532DU	33533DU
 <p>CLICKLINE® DUVAL Grasping Forceps</p> <p>44</p>			

Please note:

For **CLICKLINE®** instruments only the **individual component parts** are numbered. The catalog number for the **complete instrument** is not on the instrument. Instruments with **handles without connector pin** for unipolar coagulation are shown against the **blue** background. The colour **green** indicates the inserts.

RoBi® Bipolar Grasping Forceps

RoBi® – rotational, can be dismantle
with connector pin for bipolar coagulation, CLERMONT-FERRAND Model,
size 5 mm, trocar size 6 mm



Outer Sheath	Handle
	38151
36 cm	
43 cm	

Double-action jaws:

Working Insert No.	Catalog number for the complete instrument
38610ON	38651ON
38710ON	38751ON
	RoBi® Grasping Forceps, CLERMONT-FERRAND Model, fenestrated, with fine atraumatic serration, color code: light blue

38610MD	38651MD
38710MD	38751MD
	RoBi® KELLY Grasping Forceps, CLERMONT- FERRAND model, suitable for dissection, color code: light blue

Single-action jaws:

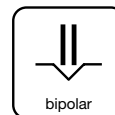
38610CS	38651CS
	RoBi® Grasping Forceps, CLERMONT-FERRAND Model, for fine dissection, grasping and bipolar coagulation of fine structures, color code: light blue

Please note:

For **RoBi® Bipolar Grasping Forceps** instruments only the **individual component parts** are numbered. The catalog number for the **complete instrument**, as shown above against the **red** background is not on the instrument. The colour **green** indicates the inserts.

RoBi® Bipolar Scissors

RoBi® – rotational, can be dismantle
with connector pin for bipolar coagulation, CLERMONT-FERRAND Model,
size 5 mm, trocar size 6 mm



Outer Sheath	Handle
	38151
36 CM	
43 CM	

Single-action jaws:

Working Insert No.	Catalog number for the complete instrument
38610MT	38651MT
	RoBi® Scissors, CLERMONT-FERRAND Model, action jaws straight, for cutting of vessels and tissue layers, color code: light blue

38610MZ	38651MZ
	RoBi® Scissors, CLERMONT-FERRAND Model, action jaws straight, serrated, color code: light blue

Double-action jaws:

38610MW	38651MW
38710MW	38751MW
	RoBi® METZENBAUM Scissors, CLERMONT- FERRAND model, curved slender blades, double action jaws, color code: light blue

Please note:

For **RoBi® Bipolar Grasping Forceps** instruments only the **individual component parts** are numbered. The catalog number for the **complete instrument**, as shown above against the **red** background is not on the instrument. The colour **green** indicates the inserts.

Surgical Sponge Holder

Size 5 mm and 10 mm

Multiple puncture approach

Operating instruments, **lengths 30 cm**,
for use with trocar size 6 and 11 mm

Special Features:

**The instrument may be used as an atraumatic retractor and for blunt dissection.
The sponge can easily be replaced by push-button control.**



32340PT



32340PT

Surgical Sponge Holder,
self-retaining, size 5 mm, length 30 cm,
including:
Handle
Outer Sheath, insulated
Sponge Holder Insert



32540PT

Same, size 10 mm

Retractor for Gastric Banding

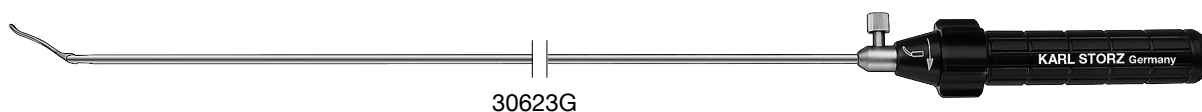
Size 5 and 10 mm

Operating instrument, length 36 cm,
for use with trocars size 6 and 11 mm

Special Features:

- Distal tip articulating up to 90°
- Blunt, atraumatic retractor element
- Fenestrated retractor element

The instrument is used as a blunt retractor in stomach and bowel surgery.
In gastric banding, the stomach band is anchored in the fenestration and pulled
around the esophagus.



30623G

Retractor for Gastric Banding,
size 5 mm, length 36 cm



30623GB

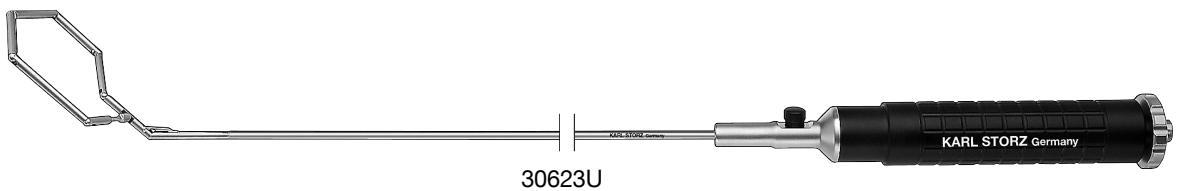
Same, size 10 mm

CUSCHIERI Liver Retractor

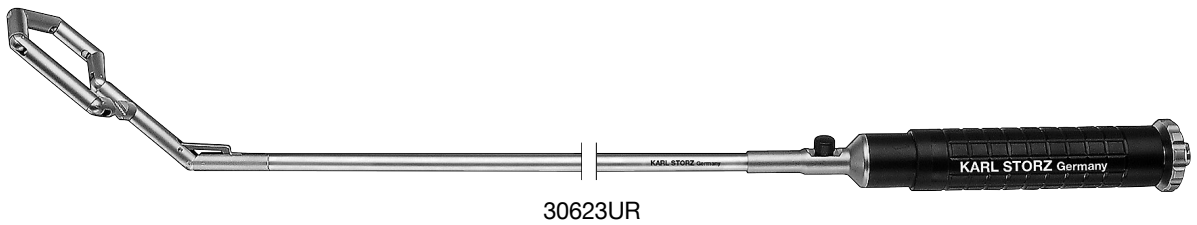
Size 5 and 10 mm

Multiple puncture approach

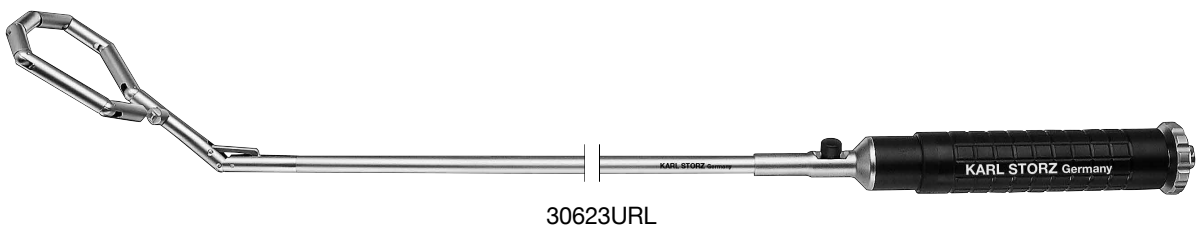
Operating instrument, length 36 cm,
for use with trocars size 6 mm



30623U CUSCHIERI Retractor,
size 5 mm, length 36 cm



30623UR CUSCHIERI Retractor,
size 10 mm, length 36 cm

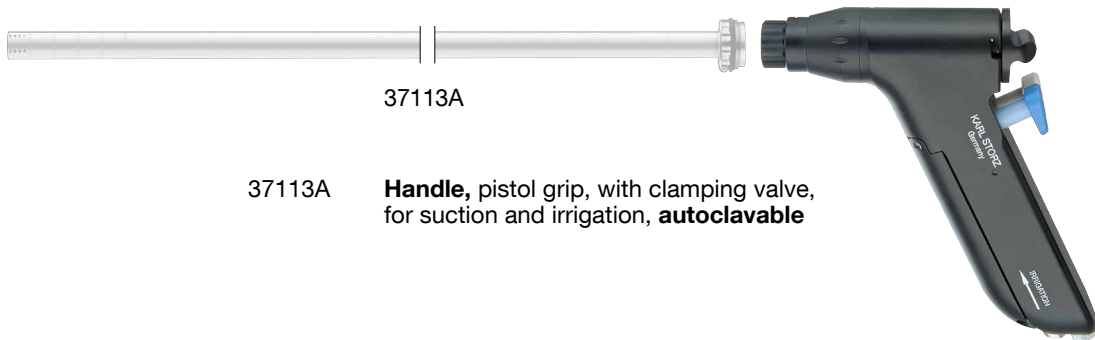


30623URL CUSCHIERI Retractor,
large contact surface, size 10 mm, length 36 cm

Handles for Suction and Irrigation



37112A **Handle**, straight, with clamping valve, for suction and irrigation, **autoclavable**



37113A **Handle**, pistol grip, with clamping valve, for suction and irrigation, **autoclavable**



37360LH **Suction and Irrigation Tube**, with lateral holes, size 5 mm, length 36 cm, for use with suction and irrigation handles

Dissecting Electrodes

with Exchangeable Electrode Tip

Insulated Sheath with Connector Pin for Uniplar Coagulation



30775UF



30775UF **Coagulation and Dissection Electrode**, L-shaped, with connector pin for unipolar coagulation, size 5 mm, length 36 cm
including:
Outer Sheath, insulated
Plastic Handle
Electrode, L-shaped

30775UFE **Exchangeable Electrode Tip**, L-shaped, autoclavable, package of 6

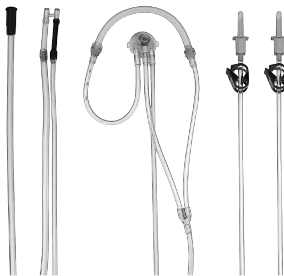Tubing Sets

for use with Handles 37112A and 37113A



031133-10

031133-10* **Tubing Set**, for single use, sterile, package of 10, for use with Suction and Irrigation Handles 37112A and 37113A



031218-10

031218-10* **Tubing Set**, with two puncture cannulas, for single use, sterile, package of 10, for use with Handles 37112A (straight) and 37113A (pistol grip) in combination with KARL STORZ HAMOU® ENDOMAT® 26331009-1



031219-10

031219-10* **Tubing Set**, with two puncture cannulas, for single use, sterile, package of 10, for use with Handles 37112A (straight) and 37113A (pistol grip) in combination with KARL STORZ ENDOMAT® LC



031134-10

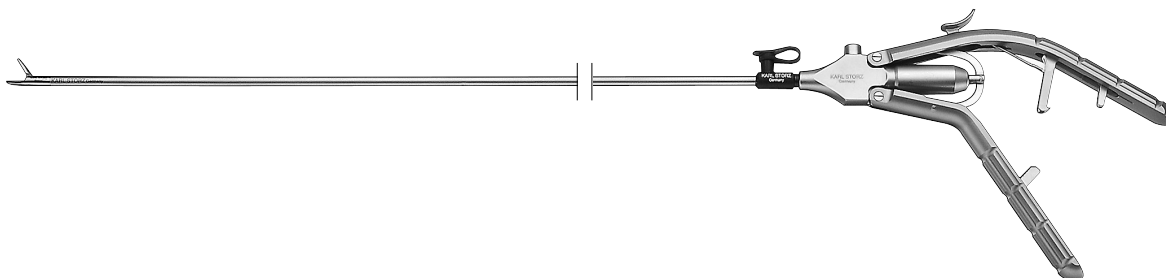
031134-10* **Tubing Set**, for single use, sterile, package of 10, for use with Suction and Irrigation Handles 37112A and 37113A in combination with silicone tube inner diameter 5 mm at the patient end, for use with KARL STORZ HAMOU® ENDOMAT® 26331101-1 in combination with Tubing Set 031518-10



mtp medical technical promotion gmbh,
Take-Off GewerbePark 46, D-78579 Neuhausen ob Eck, Germany

KOH Macro Needle Holder

dismantable



KOH Macro Needle Holder, size 5 mm, dismantable, including:

- Handle
- Outer Sheath
- Working Insert

Cleaning and sterilization are gaining increasing importance for KARL STORZ as a manufacturer of surgical instruments.

Similar to all our surgical instruments, the cleaning and hygiene of our needle holders also play an important role.

For cleaning and sterilization, the KOH macro needle holders can be disassembled into their main components.

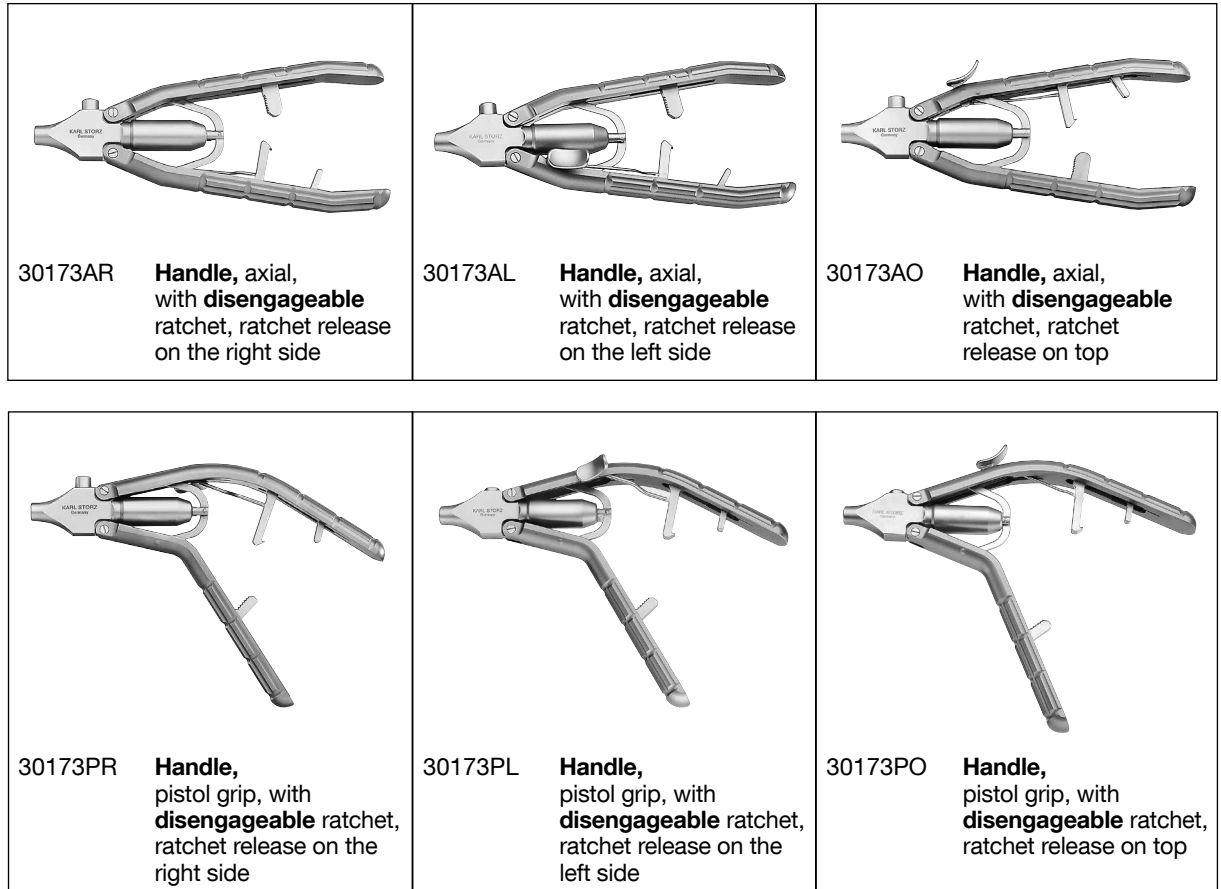
This unique reusable three-piece design offers the user the following benefits:

- Can be disassembled into three separate components
- Autoclavable
- Cleaning adaptor
- Choice of six different handles and three different working inserts
- With tungsten carbide inserts
- In the event of damage, only the component with the defect needs to be replaced

Handles and Outer Tubes

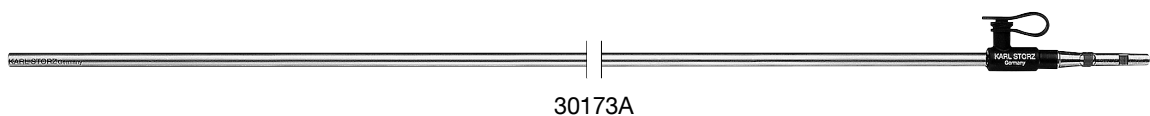
KOH Macro Needle Holders, dismantable

Handles axial and pistol grip with disengageable ratchet



Metal Outer Sheath

Size 5 mm

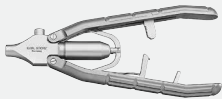
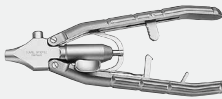
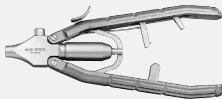





with LUER-Lock connector for cleaning	Length
30173A	33 cm
30178A	43 cm





KOH Macro Needle Holder

dismantlable

Size 5 mm

Working Length	Handle		
	30173AR	30173AL	30173AO
33 cm			
43 cm			







Single-action jaws

Insert No.	Complete Instrument		
30173R	30173RAR	30173RAL	30173RAO
30178R	30178RAR	30178RAL	30178RAO
	KOH Macro Needle Holder , dismantling, jaws curved to right, with tungsten carbide inserts, for use with suture material size 0/0 – 7/0		
30173L	30173LAR	30173LAL	30173LAO
30178L	30178LAR	30178LAL	30178LAO
	KOH Macro Needle Holder , dismantling, jaws curved to left, with tungsten carbide inserts, for use with suture material size 0/0 – 7/0		
30173F	30173FAR	30173FAL	30173FAO
30178F	30178FAR	30178FAL	30178FAO
	KOH Macro Needle Holder , dismantling, straight jaws, with tungsten carbide inserts, for use with suture material size 0/0 – 7/0		
30173G	30173GAR	30173GAL	30173GAO
	KOH Macro Needle Holder , dismantling, straight jaws		





KOH Macro Needle Holder

dismantable

Size 5 mm

Working Length	Handle		
	30173PR	30173PL	30173PO
33 cm			
43 cm			

Single-action jaws

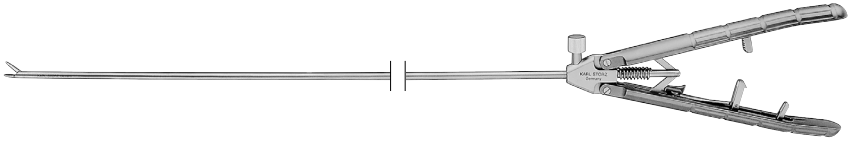
Insert No.	Complete Instrument		
30173R	30173RPR	30173RPL	30173RPO
30178R	30178RPR	30178RPL	30178RPO
	KOH Macro Needle Holder , dismantling, jaws curved to right, with tungsten carbide inserts, for use with suture material size 0/0 – 7/0		
30173L	30173LPR	30173LPL	30173LPO
30178L	30178LPR	30178LPL	30178LPO
	KOH Macro Needle Holder , dismantling, jaws curved to left, with tungsten carbide inserts, for use with suture material size 0/0 – 7/0		
30173F	30173FPR	30173FPL	30173FPO
30178F	30178FPR	30178FPL	30178FPO
	KOH Macro Needle Holder , dismantling, straight jaws, with tungsten carbide inserts, for use with suture material size 0/0 – 7/0		
30173G	30173GPR	30173GPL	30173GPO
	KOH Macro Needle Holder , dismantling, straight jaws		




KOH Macro Needle Holder

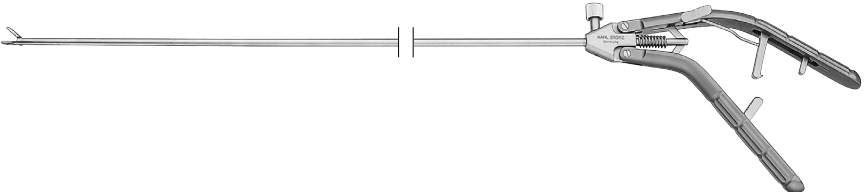
size 5 mm




Multiple puncture approach

Operating instrument, length 33 cm,
for use with trocars size 6 m

Working Length	Instrument
33 cm	
43 cm	

Distal End	Instrument	
	26173KAF	KOH Macro Needle Holder , with tungsten carbide insert, axial handle with disengageable ratchet, ratchet position right, jaws straight
	26178KAF	
	26173KAL	KOH Macro Needle Holder , with tungsten carbide insert, axial handle with disengageable ratchet, ratchet position right, jaws curved to left
	26178KAL	
	26173KAR	KOH Macro Needle Holder , with tungsten carbide insert, axial handle with disengageable ratchet, ratchet position left, jaws curved to right
	26178KAR	

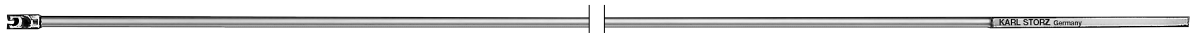
Working Length	Instrument
33 cm	
43 cm	

Distal End	Instrument	
	26173KPF	KOH Macro Needle Holder , with tungsten carbide insert, pistol handle with disengageable ratchet, ratchet position left, jaws straight
	26178KPF	
	26173KPL	KOH Macro Needle Holder , with tungsten carbide insert, pistol handle with disengageable ratchet, ratchet position left, jaws curved to left
	26178KPL	
	26173KPR	KOH Macro Needle Holder , with tungsten carbide insert, pistol handle with disengageable ratchet, ratchet position right, jaws curved to right
	26178KPR	

Knot Tier

Size 5 mm

Trocar size 6 mm



26596SK



26596SK

KÖCKERLING Knot Tier,
for extracorporeal knotting,
size 5 mm, length 36 cm

Clip Applicator

Size 10 mm

Multiple puncture approach

Operating instrument, length 33 cm,
for use with trocar size 11 m



30444LR

Clip Applicator, dismantling, rotating,
size 10 mm, length 36 cm,
for PILLING-WECK Titanium Clips 30460 AL
(medium-large), with ratchet to lock the
jaw holding the clip,
including:

Metal Handle, with ratchet

Metal Outer Sheath

Forceps Insert



Originalgröße

30460AL

PILLING-WECK Titanium Clip, medium-large,
box with 16 sterile cartridges, 10 clips each,
for use with Clip Applicator 30444LR

Caution:

The use of other clips than indicated, can lead to damage
of the mouthpiece.

IMAGE1 S Camera System



Economical and future-proof

- Modular concept for flexible, rigid and 3D endoscopy as well as new technologies
- Forward and backward compatibility with video endoscopes and FULL HD camera heads

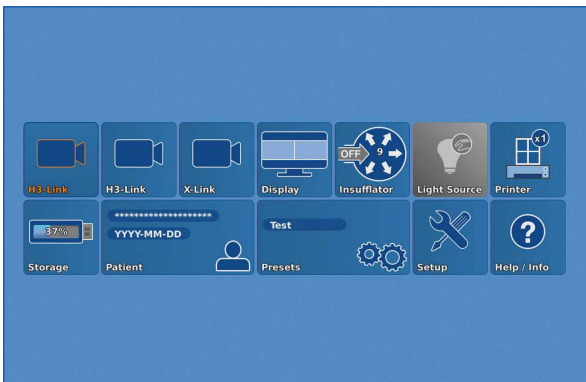


- Sustainable investment
- Compatible with all light sources



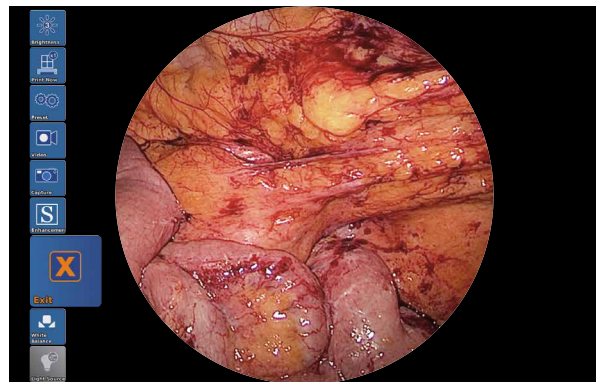
Innovative Design

- Dashboard: Complete overview with intuitive menu guidance
- Live menu: User-friendly and customizable
- Intelligent icons: Graphic representation changes when settings of connected devices or the entire system are adjusted




Dashboard

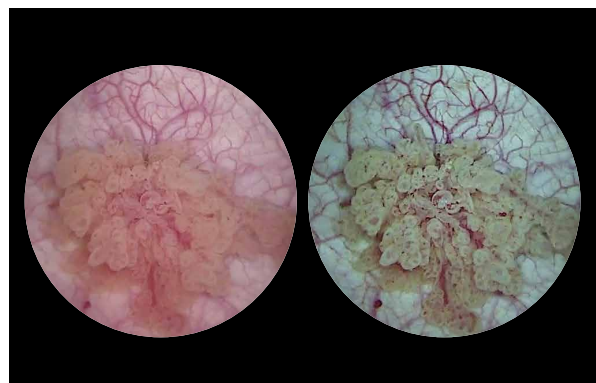
- Automatic light source control
- Side-by-side view: Parallel display of standard image and the Visualization mode
- Multiple source control: IMAGE1 S allows the simultaneous display, processing and documentation of image information from two connected image sources, e.g., for hybrid operations



Live menu



Intelligent icons



Side-by-side view: Parallel display of standard image and Visualization mode

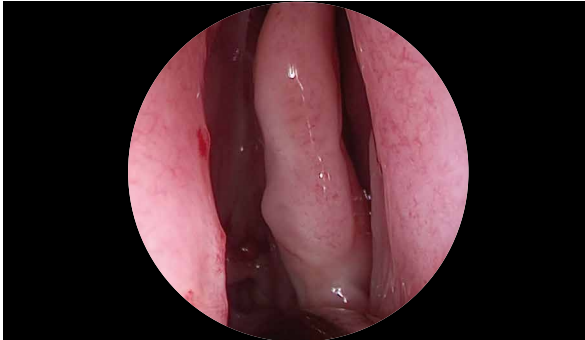
IMAGE1 S Camera System



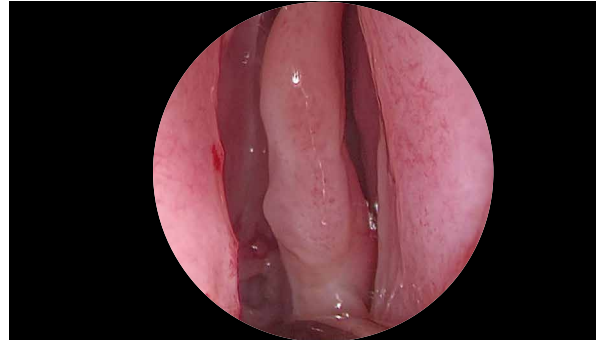
FULL HD Imaging

- Very high quality of endoscopic images in FULL HD
- Natural color rendition

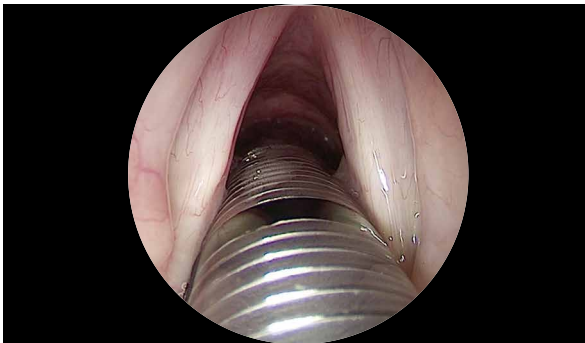
- Multiple IMAGE1 S technologies for homogeneous illumination, contrast enhancement and color shifting



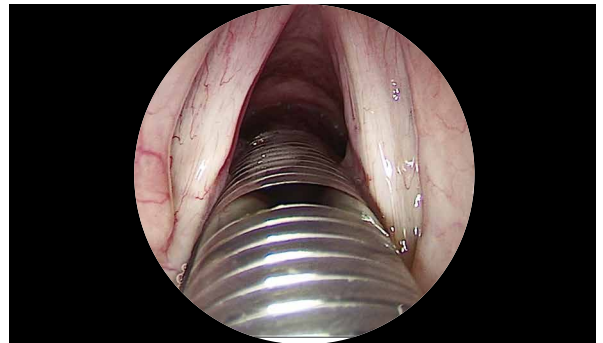
FULL HD image



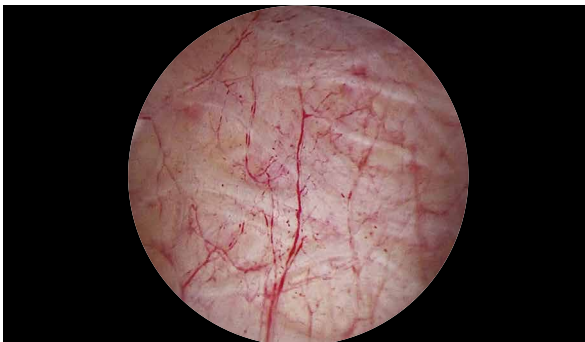CLARA



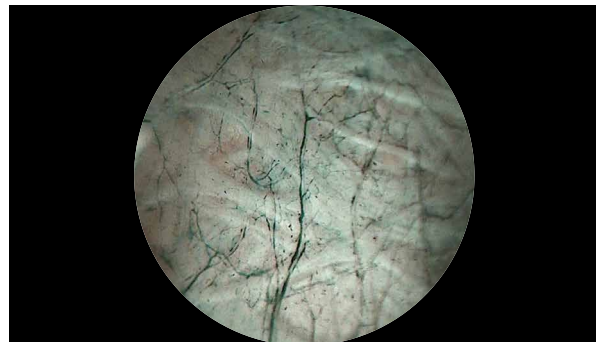FULL HD image



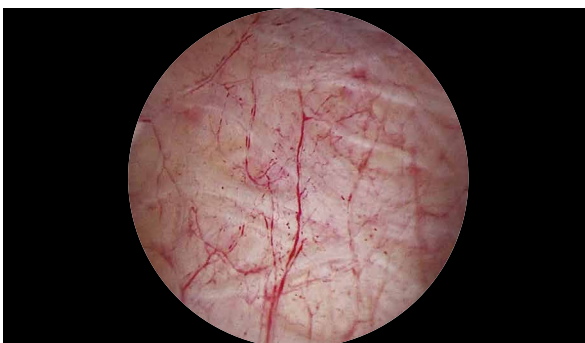CHROMA



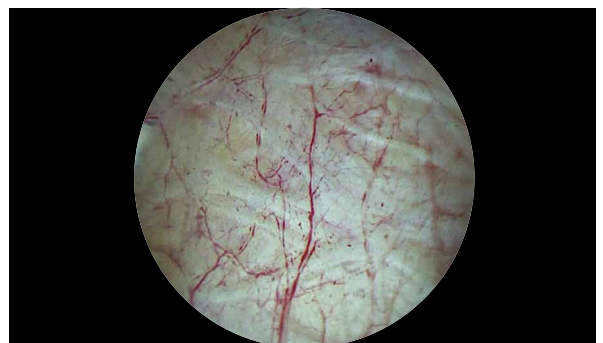FULL HD image



SPECTRA A*



FULL HD image



SPECTRA B**

* SPECTRA A: Not for sale in the U.S.

** SPECTRA B: Not for sale in the U.S.

IMAGE1 S Camera System



TC 200EN

- TC200EN* **IMAGE1 S CONNECT**, connect module, for use with up to 3 link modules, resolution 1920 x 1080 pixels, with integrated KARL STORZ-SCB and digital Image Processing Module, power supply 100–120 VAC/200–240 VAC, 50/60 Hz including:
- Mains Cord**, length 300 cm
 - DVI-D Connecting Cable**, length 300 cm
 - SCB Connecting Cable**, length 100 cm
 - USB Flash Drive**, 32 GB, USB silicone keyboard, with touchpad, US
- * Available in the following languages: DE, ES, FR, IT, PT, RU

Specifications:

HD video outputs	- 2x DVI-D - 1x 3G-SDI	Power supply	100–120 VAC/200–240 VAC
Format signal outputs	1920 x 1080p, 50/60 Hz	Power frequency	50/60 Hz
LINK video inputs	3x	Protection class	I, CF-Defib
USB interface	4x USB, (2x front, 2x rear)	Dimensions w x h x d	305 x 54 x 320 mm
SCB interface	2x 6-pin mini-DIN	Weight	2.1 kg

For use with IMAGE1 S IMAGE1 S CONNECT Module TC200EN



TC300

- TC300 **IMAGE1 S H3-LINK**, link module, for use with IMAGE1 FULL HD three-chip camera heads, power supply 100–120 VAC/200–240 VAC, 50/60 Hz, **for use with IMAGE1 S CONNECT TC 200EN** including:
- Mains Cord**, length 300 cm
 - Link Cable**, length 20 cm

Specifications:

Camera System	TC300 (H3-Link)
Supported camera heads/video endoscopes	TH100, TH101, TH102, TH103, TH104, TH106 (fully compatible with IMAGE1 S) 22 2200 55-3, 22 2200 56-3, 22 2200 53-3, 22 2200 60-3, 22 2200 61-3, 22 2200 54-3, 22 2200 85-3 (compatible without IMAGE1 S technologies CLARA, CHROMA, SPECTRA*)
LINK video outputs	1x
Power supply	100–120 VAC/200–240 VAC
Power frequency	50/60 Hz
Protection class	I, CF-Defib
Dimensions w x h x d	305 x 54 x 320 mm
Weight	1.86 kg

* SPECTRA A: Not for sale in the U.S.

** SPECTRA B: Not for sale in the U.S.

IMAGE1 S Camera Heads



For use with IMAGE1 S Camera System
 IMAGE1 S CONNECT Module TC200EN, IMAGE1 S H3-LINK Module TC300
 and with all IMAGE1 HUB™ HD Camera Control Units



TH100

IMAGE1 S H3-Z Three-Chip FULL HD Camera Head, 50/60 Hz, IMAGE1 S compatible, progressive scan, soakable, gas- and plasma-sterilizable, with integrated Parfocal Zoom Lens, focal length $f = 15-31$ mm (2x), 2 freely programmable camera head buttons, for use with IMAGE1 S and IMAGE1 HUB™ HD/HD

Specifications:

IMAGE1 FULL HD Camera Heads	IMAGE1 S H3-Z
Product no.	TH100
Image sensor	3x 1/3" CCD chip
Dimensions w x h x d	39 x 49 x 114 mm
Weight	270 g
Optical interface	integrated Parfocal Zoom Lens, $f = 15-31$ mm (2x)
Min. sensitivity	F 1.4/1.17 Lux
Grip mechanism	standard eyepiece adaptor
Cable	non-detachable
Cable length	300 cm



TH104

IMAGE1 S H3-ZA Three-Chip FULL HD Camera Head, 50/60 Hz, IMAGE1 S compatible, **autoclavable**, progressive scan, soakable, gas- and plasma-sterilizable, with integrated Parfocal Zoom Lens, focal length $f = 15-31$ mm (2x), 2 freely programmable camera head buttons, for use with IMAGE1 S and IMAGE1 HUB™ HD/HD

Specifications:

IMAGE1 FULL HD Camera Heads	IMAGE1 S H3-ZA
Product no.	TH104
Image sensor	3x 1/3" CCD chip
Dimensions w x h x d	39 x 49 x 100 mm
Weight	299 g
Optical interface	integrated Parfocal Zoom Lens, $f = 15-31$ mm (2x)
Min. sensitivity	F 1.4/1.17 Lux
Grip mechanism	standard eyepiece adaptor
Cable	non-detachable
Cable length	300 cm

Monitors



9619NB

9619NB

19" HD Monitor,
color systems **PAL/NTSC**, max. screen
resolution 1280 x 1024, image format 4:3,
power supply 100–240 VAC, 50/60 Hz,
wall-mounted with VESA 100 adaption,
including:
External 24 VDC Power Supply
Mains Cord



9826NB

9826NB

26" FULL HD Monitor,
wall-mounted with VESA 100 adaption,
color systems **PAL/NTSC**,
max. screen resolution 1920 x 1080,
image format 16:9,
power supply 100–240 VAC, 50/60 Hz
including:
External 24 VDC Power Supply
Mains Cord

Monitors

KARL STORZ HD and FULL HD Monitors	19"	26"
Wall-mounted with VESA 100 adaption	9619NB	9826NB
Inputs:		
DVI-D	●	●
Fibre Optic		
3G-SDI		●
RGBS (VGA)	●	●
S-Video	●	●
Composite/FBAS	●	●
Outputs:		
DVI-D	●	●
S-Video	●	
Composite/FBAS	●	●
RGBS (VGA)	●	
3G-SDI		●
Signal Format Display:		
4:3	●	●
5:4	●	●
16:9	●	●
Picture-in-Picture	●	●
PAL/NTSC compatible	●	●

Optional accessories:

9826SF **Pedestal**, for monitor 9826NB

9626SF **Pedestal**, for monitor 9619NB

Specifications:

KARL STORZ HD and FULL HD Monitors	19"	26"
Desktop with pedestal	optional	optional
Product no.	9619NB	9826NB
Brightness	200 cd/m ² (typ)	500 cd/m ² (typ)
Max. viewing angle	178° vertical	178° vertical
Pixel distance	0.29 mm	0.3 mm
Reaction time	5 ms	8 ms
Contrast ratio	700:1	1400:1
Mount	100 mm VESA	100 mm VESA
Weight	7.6 kg	7.7 kg
Rated power	28 W	72 W
Operating conditions	0–40°C	5–35°C
Storage	-20–60°C	-20–60°C
Rel. humidity	max. 85%	max. 85%
Dimensions w x h x d	469.5 x 416 x 75.5 mm	643 x 396 x 87 mm
Power supply	100–240 VAC	100–240 VAC
Certified to	EN 60601-1, protection class IPX0	EN 60601-1, UL 60601-1, MDD93/42/EEC, protection class IPX2

Accessories for Video Documentation



For use with telescopes, diameter 10 mm:

495 NCS **Fiber Optic Light Cable**,
with straight connector,
extremely heat-resistant,
diameter 4.8 mm, length 250 cm

For use with telescopes, diameter 5 mm:

495 NA **Fiber Optic Light Cable**,
diameter 3.5 mm, length 230 cm

Cold Light Fountain XENON 300 SCB



20133101-1 **Cold Light Fountain XENON 300 SCB**
with built-in antifog air-pump, and integrated
KARL STORZ Communication Bus System SCB
power supply:

100–125 VAC/220–240 VAC, 50/60 Hz

including:

Mains Cord

Silicone Tubing Set, autoclavable, length 250 cm

SCB Connecting Cable, length 100 cm

20133027 **Spare Lamp Module XENON**
with heat sink, 300 watt, 15 volt

20133028 **XENON Spare Lamp**, only,
300 watt, 15 volt

Cold Light Fountain Power LED 175 SCB



20161401-1 **Cold Light Fountain Power LED 175 SCB**,
with integrated SCB, high-performance LED
and one KARL STORZ light outlet,
power supply 110–240 VAC, 50/60 Hz

including:

Cold Light Fountain Power LED

Mains Cord

SCB Connecting Cable, length 100 cm

20132026 **Xenon-Spare-Lamp**, 175 Watt, 15 Volt

THERMOFLATOR® with KARL STORZ SCB

with High Flow Insufflation (30 l/min.)

26 4320 08-1 **THERMOFLATOR® SCB**

including:

THERMOFLATOR® with KARL STORZ SCB

power supply 100 – 240 VAC, 50/60 Hz

Mains Cord**OPTITHERM® Heating Element**, sterilizable**Silicone Tubing Set**, sterilizable**Universal Wrench****SCB Connecting Cable**, length 100 cm* **CO₂/N₂O Gas Filter**, sterile,
for single use, package of 10

Subject to the customer's application-specific requirements additional accessories must be ordered separately.

ENDOFLATOR® 40 with KARL STORZ SCB

with High Flow Insufflation (40 l/min.)



UI400S1

ENDOFLATOR® 40 SCB,

Set, with integrated SCB module,

power supply 100 - 240 VAC, 50/60 Hz

including:

ENDOFLATOR® 40**Mains Cord**, length 300 cm**SCB Connecting Cable**, length 100 cm**Universal Wrench****Insufflation Tubing Set**, with gas filter, sterile,
for single use, package of 5*

Subject to the customer's application-specific requirements additional accessories must be ordered separately.

HAMOU® ENDOMAT® with KARL STORZ SCB

Suction and Irrigation System

263311 01-1 **HAMOU® ENDOMAT® SCB**,
power supply 100 – 240 VAC, 50/60 Hz

including:

Mains Cord5x **HYST Tubing Set***, for single use5x **LAP Tubing Set***, for single use**SCB Connecting Cable**, length 100 cm**VACUsafe Promotion Pack Suction***, 2 l

Subject to the customer's application-specific requirements additional accessories must be ordered separately.

Equipment Cart



UG220

Equipment Cart

wide, high, rides on 4 antistatic dual wheels equipped with locking brakes 3 shelves, mains switch on top cover, central beam with integrated electrical subdistributors with 12 sockets, holder for power supplies, potential earth connectors and cable winding on the outside,

Dimensions:

Equipment cart: 830 x 1474 x 730 mm (w x h x d),
shelf: 630 x 510 mm (w x d),
caster diameter: 150 mm

including:

Base module equipment cart, wide

Cover equipment, equipment cart wide

Beam package equipment, equipment cart high


3x **Shelf**, wide

Drawer unit with lock, wide

2x **Equipment rail**, long

Camera holder

UG220



UG540

Monitor Swivel Arm,

height and side adjustable, can be turned to the left or the right side, swivel range 180°, overhang 780 mm, overhang from centre 1170 mm, load capacity max. 15 kg, with monitor fixation VESA 75/100, for usage with equipment carts UGxxx

UG540

Recommended Accessories for Equipment Cart



UG310

UG310

Isolation Transformer,

200 V–240 V; 2000 VA with 3 special mains socket, expulsion fuses, 3 grounding plugs, dimensions: 330 x 90 x 495 mm (w x h x d), for usage with equipment carts UGxxx



UG410

UG410

Earth Leakage Monitor,

200 V–240 V, for mounting at equipment cart, control panel dimensions: 44 x 80 x 29 mm (w x h x d), for usage with isolation transformer UG310



UG510

UG510

Monitor Holding Arm,

height adjustable, inclinable, mountable on left or right, turning radius approx. 320°, overhang 530 mm, load capacity max. 15 kg, monitor fixation VESA 75/100, for usage with equipment carts UGxxx

Notes

**WITH COMPLIMENTS OF
KARL STORZ—ENDOSKOPE**